



Malignant Parotid Salivary Gland Tumour: Mucoepidermoid Carcinoma-Treated with Surgical Excision and Adjuvant Therapy

Pankaj Goyal ^{a*}, Kishan Kumawat ^a and Itisha Dhiman ^b

^a Apollo E.N.T. Hospital, Jodhpur, Rajasthan, India.

^b SRL Diagnostics, Shastri Nagar, Jodhpur, Rajasthan, India.

Authors' contributions

This work was carried out in collaboration among all authors. All authors read and approved the final manuscript.

Article Information

Open Peer Review History:

This journal follows the Advanced Open Peer Review policy. Identity of the Reviewers, Editor(s) and additional Reviewers, peer review comments, different versions of the manuscript, comments of the editors, etc are available here: <https://www.sdiarticle5.com/review-history/98053>

Case Report

Received: 19/01/2023

Accepted: 22/03/2023

Published: 25/03/2023

ABSTRACT

Salivary gland tumours are quite rare. The most common symptom of salivary gland tumours is an expanding, painless swelling. Most are benign and are found in the parotid glands. The biggest obstacle in handling them is the difficulty in differentiating benign from malignant tumours. However, the majority of cases will require surgical excision as a means of arriving at a certain diagnosis. The most common type of malignant tumour of the major salivary glands is mucoepidermoid carcinoma (MEC). Investigations like fine needle aspiration cytology and Magnetic Resonance imaging scans offer some important information in this regard. Surgery alone can effectively cure early-stage low-grade malignancies, but postoperative radiation is necessary for more advanced, high-grade tumours that have metastasized to nearby lymph nodes. We presented a case of mucoepidermoid parotid carcinoma (intermediate grade) in a twenty-two-year-old male patient who was treated with surgical excision and post-operative adjuvant chemo-radiotherapy.

*Corresponding author: E-mail: pank1414@gmail.com;

Keywords: Parotid gland; mucoepidermoid carcinoma; major salivary gland; MRI; surgical excision; chemo-radiotherapy.

1. INTRODUCTION

Salivary gland tumours make up less than 1% of all cancers in all body sites but about 5% of head and neck tumours [1]. Nonetheless, despite being uncommon, these carcinomas represent a wide variety of histological subtypes. Mucoepidermoid carcinoma (MEC) is the most prevalent of them, accounting for up to 50% of parotid malignancies and 30% to 40% of all cancers of the salivary glands [2]. The excretory ducts' pluripotent reserve cells, which have the ability to differentiate into squamous, columnar, and mucous cells, are thought to be the source of MEC of the salivary gland [3]. The name "mucoepidermoid" was first used in 1945 by Stewart and colleagues [4] to describe a specific salivary gland tumour that was distinguished by a mixed pattern of the two primary cell types epidermoid and mucus-producing cells.

A third cell type, the intermediate cell, which is neither entirely epidermoid nor mucous, is frequently found. It is believed that intermediate cells can differentiate into mucous or epidermoid cells. The histologic makeup, biological function, and clinical course of MEC differ due to this cellular heterogeneity. There are differing views on the proper grading, categorization, and management of these tumours due to their relative rarity and the remarkable variety in their biological behaviour [5-8]. Mucinous and epidermoid cells are both present in mucoepidermoid carcinoma tumours, while multiple other cell types are also present. Moreover, there is a lot of heterogeneity in the MEC cell type, distribution, and growth pattern, which results in a number of histological variances [9]. Improvements in immunohistochemistry, cytogenetics, and molecular genetics have given information crucial for reliably distinguishing MECs from neoplasms with a similar pathology and have probably made older research' inclusion criteria less accurate [10,11]. Histological grade and tumour stage have been linked to the recurrent and metastatic behaviour of MEC, and they have been established in numerous retrospective investigations as consistently significant prognostic variables [5,12-14]. These elements are frequently taken into account when developing treatment plans. Nonetheless, there is still debate over the best course of treatment for the various histological grades and stages.

Early-stage low-grade malignancies can be successfully treated with surgery alone, but more advanced, high-grade tumours that have metastasized to adjacent lymph nodes require postoperative radiation. Although radiation methods have advanced over the past 20 years, their effects on cancers of the salivary glands have not been sufficiently researched. Trials of systemic treatment have also had mixed results [14].

2. CASE REPORT

A twenty-two-year-old male patient presented to our Apollo E.N.T. Hospital, Jodhpur, Rajasthan with a two-year history of right sided preauricular and neck swelling. The patient had been operated one year back for the same complained and was diagnosed with pleomorphic adenoma. However, post-surgery swelling gradually increased in size up to the present size of approximately 5 x 3cm, and he now had cervical lymph node enlargement (Fig. 1). There was no prior history of discomfort, fever, or facial paralysis or weakness and mouth-opening issues. No addiction was acknowledged by our patient, who also had no concomitant conditions.

Upon examination, a right parotid tumour measuring 5 x 3 cm was found, along with palpable level II and III lymph nodes. Function of the facial nerve was unaffected. Patient had been advised for contrast enhanced magnetic resonance imaging (MRI) and posted for fine needle aspiration cytology (FNAC). MRI (T2 weighted image, Fig. 2) revealed intermediate to low signal intensity of right parotid mass involving the superior and deep lobe of the gland. FNAC reported it as intermediate grade of mucoepidermoid carcinoma. The terms and circumstances of the surgery were conveyed to the patient.

Patient was then scheduled for surgery under general anaesthesia. This procedure makes use of a modified Blair's incision that starts just anterior to the tragus, curves posteriorly towards the mastoid process, and then softly rotates anteriorly and inferiorly toward a neck skin crease (Fig. 3). The lower part of the vertical incision was elongated in this case because we planned a selective neck dissection. The skin flap is then raised anteriorly in the superficial musculoaponeurotic system's relatively

avascular plane (SMAS- Fig. 4). To maintain ear lobule sensation, the Greater auricular nerve was preserved while raising the flap. The posterior belly of the digastric muscle was identified, as was the retromandibular vein, which served as a landmark to identify the facial nerve. The mass was carefully separated while keeping the facial nerve intact. (Fig. 5) A total parotidectomy (superficial + deep lobe of parotid with preservation of facial nerve) was performed. (Fig. 6) A right-sided selective neck dissection was carried out. An absorbable vicryl suture was used

to close the surgical wound in layers after haemostasis was achieved. The patient was moved to recovery while the neck drain remained in place. On the third day, the neck drain was removed. Histopathology (Fig. 7) was performed on all neck nodes and the surgical main specimen and confirmed it as an intermediate grade mucoepidermoid parotid carcinoma with positive neck nodes. The patient underwent adjuvant chemoradiotherapy. Patient has been doing well during routine follow-up for a year (Fig. 8).

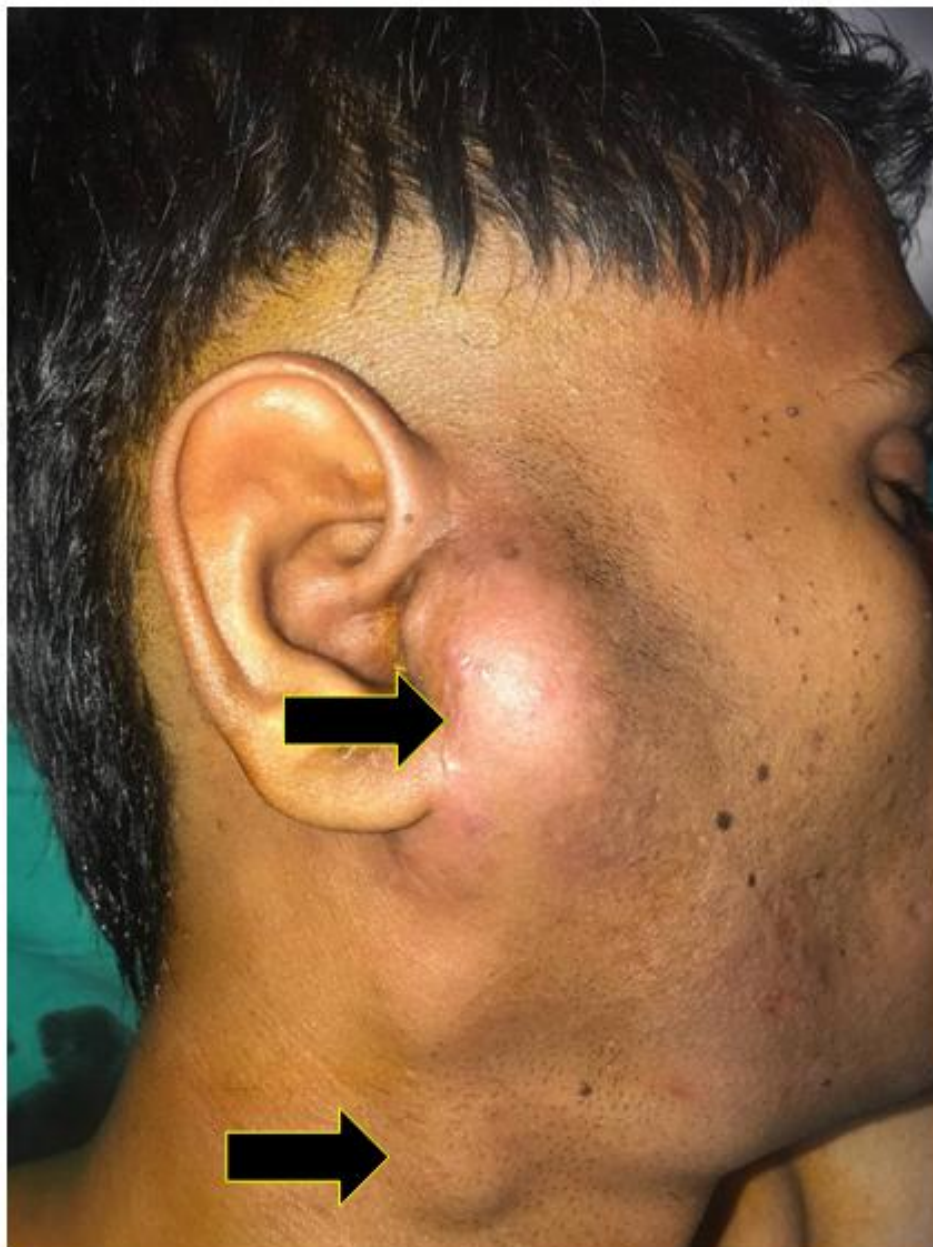

Fig. 1. Clinical picture showing right parotid swelling with level II & III neck nodes. There is a scar of previous surgery over the swelling

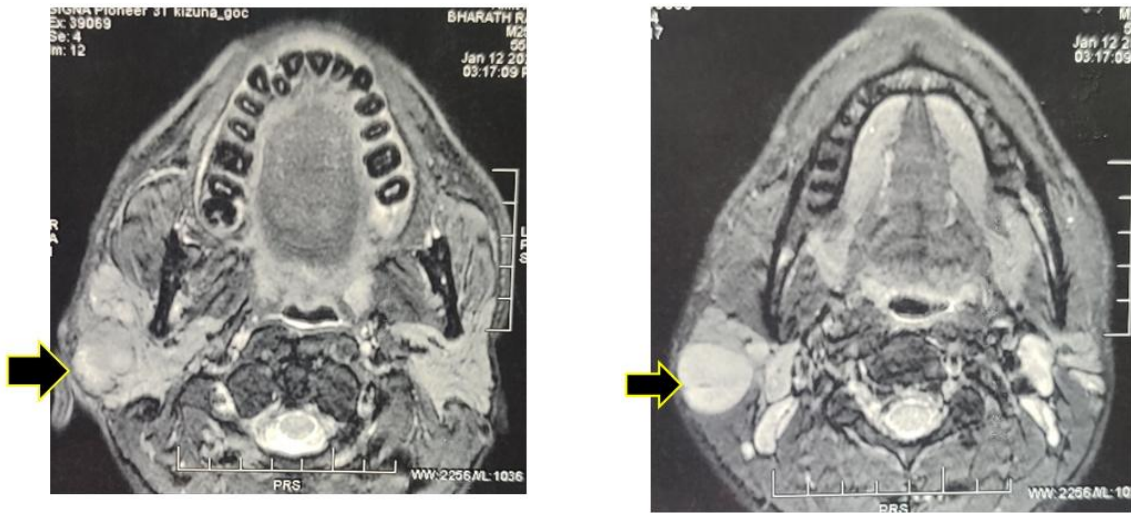


Fig. 2. MRI (T2 weighted image) revealed intermediate to low signal intensity of right parotid mass involving the superior and deep lobe of the gland

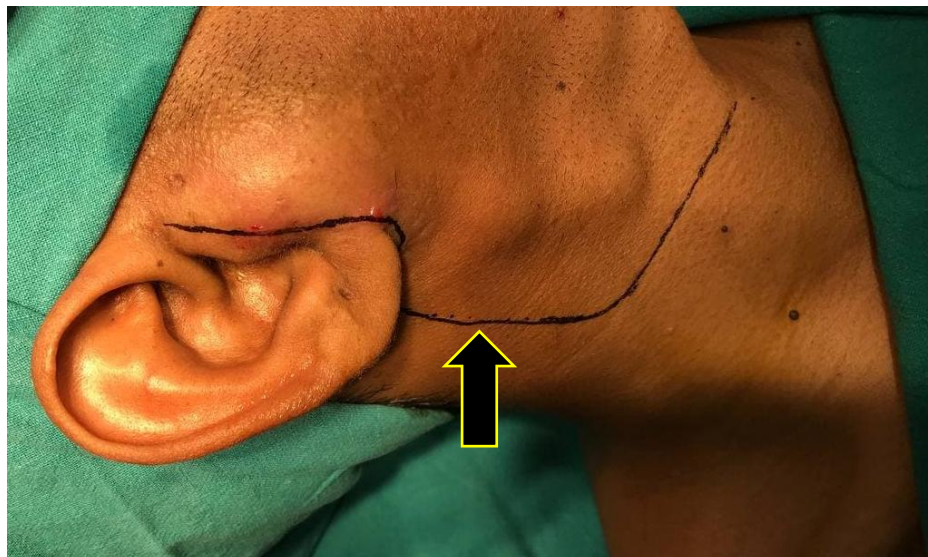


Fig. 3. Modified Blair's incision with lower neck extension for neck dissection

3. DISCUSSION

Salivary gland cancers are uncommon. The majority are benign and most are found in the parotid glands. The complexity of differentiating benign from malignant tumours is the main challenge in controlling them. The most common symptom of salivary gland tumours is an expanding, painless swelling.

The most frequent major salivary gland malignancy is mucoepidermoid carcinoma (MEC). The parotid is the most typical location for a MEC followed by the intraoral minor salivary glands. It is yet unknown what causes salivary gland cancers. While smoking and drinking

alcohol are major risk factors for the majority of other head and neck cancers, they have no bearing on salivary gland cancer. A diet high in vitamin C and low in cholesterol may help prevent salivary gland cancer, according to several research [15]. On the other hand, occupational exposures in the rubber manufacturing and woodworking industries, as well as employment in hair salons or beauty parlours, are all potential risk factors [15,16]. Salivary gland cancer risk was further elevated by a history of prior malignancies, the Epstein-Barr virus, immunosuppression, and radiation. In a Swedish study, people with Hodgkin's lymphoma had a four-fold greater risk of developing salivary gland cancer [17].

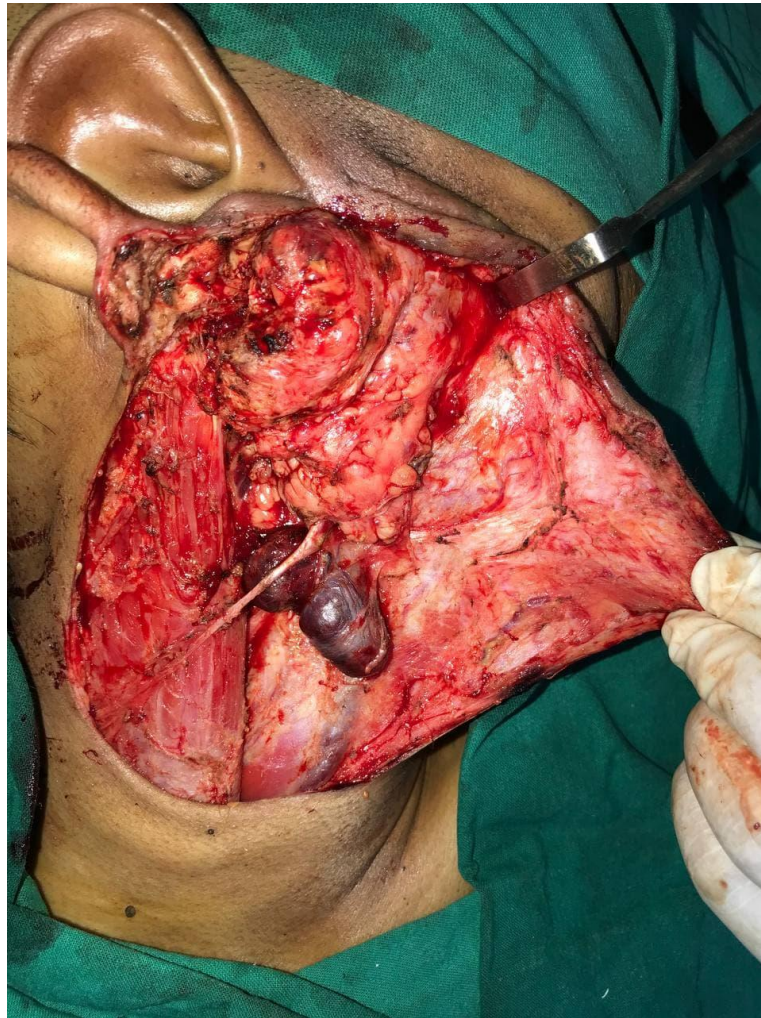

Fig. 4. Image taken during surgery that shows a lymph node and a tumour with well preserved greater auricular nerve, after the SMAS flap has been raised

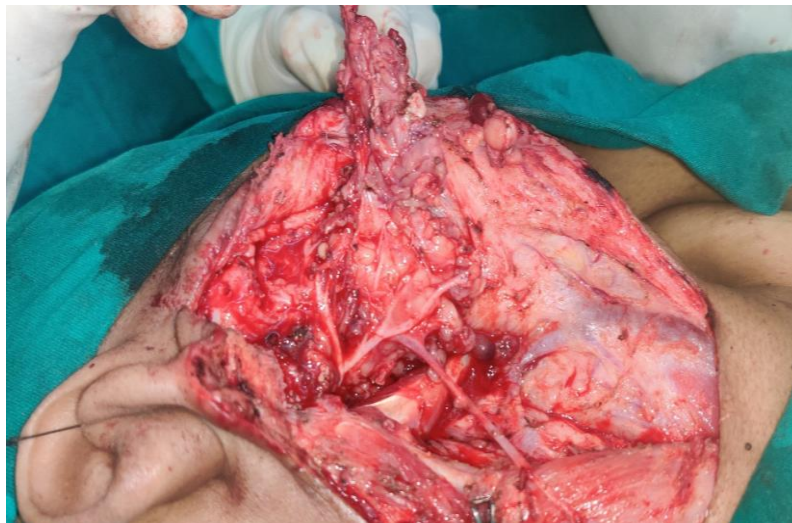

Fig. 5. An intraoperative photo showing the preserved facial nerve's branches after the excision of the tumour

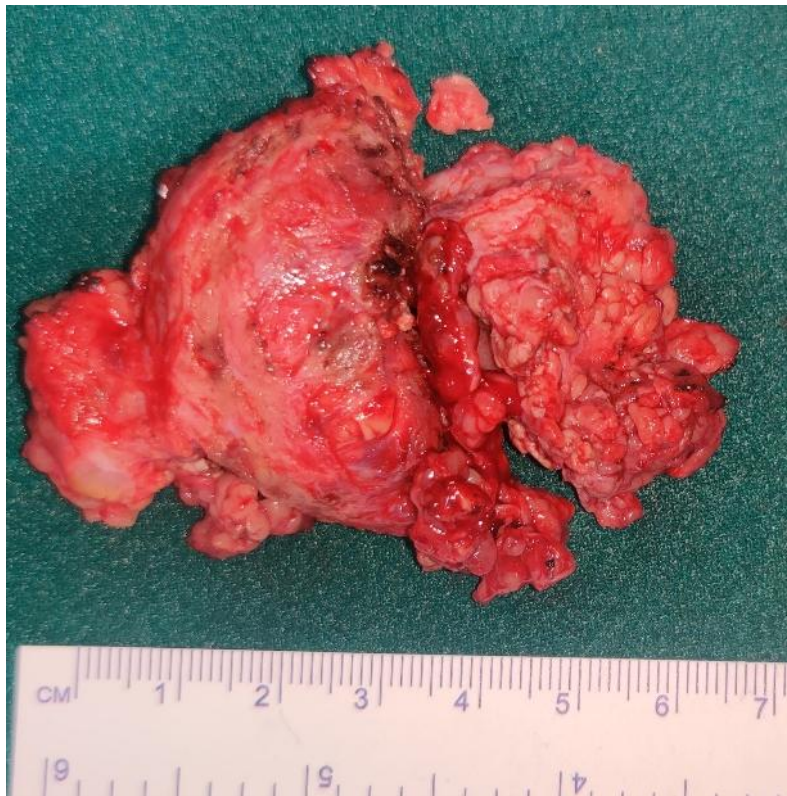

Fig. 6. Surgical specimen

The ipsilateral facial nerve palsy, abrupt tumour development, discomfort, tumour fixation to the overlying skin or underlying muscle, and cervical lymphadenopathy are clinical signs that suggest malignancy. Mucoepidermoid carcinoma is a distinct histological subtype of cancer with a wide variety of clinical behaviour. Therefore, histological grading is important in predicting how these people would do. The tumour is classified as low, middle, or high grade based on a number of histological characteristics, such as the presence of an intracystic component, neural invasion, necrosis, mitosis, lymphovascular invasion, and bone invasion [18].

According to Liu et al., the overall disease-free survival rate at five years was 80.74%, with low-grade tumour survival rates of 98.0%, intermediate tumour survival rates of 86.5%, and high tumour survival rates of 38.5% (p 0.001) [19]. Similar findings were made by Chen et al. and Ali et al., who examined the demographic distribution and cause-specific mortality of MEC and discovered that the disease-specific survival (DSS) rate was significantly lower for high-grade MEC than for all other grades [20,21].

Often times, radiological tests are used to help diagnose a salivary gland tumour. It is used to

define the tumour location, such as whether it is in the superficial or deep lobe of the parotid gland and whether it is extra glandular or intraglandular, to identify malignant characteristics, to specify local extension and invasion of surrounding tissues, and to identify regional nodal and systemic metastases. Deep lobe extension (Fig. 2), marrow infiltration, and perineural dissemination and facial nerve involvement can all be found more easily using MRI. The primary method for evaluating tumours in the superficial parotid is ultrasound.

Another inquiry that is routinely done is fine needle aspiration cytology (FNAC). With vast study series demonstrating sensitivity up to 85% and specificity up to 99%, FNAC's diagnostic output can be strong [22]. It is acceptable to say that the primary responsibilities of FNAC are surgical planning and preoperative patient counselling. If the FNAC test results are malignant, the patient can be better prepared for the duration of the procedure, the higher risk of complications, and the requirement for neck dissection or postoperative radiation. The majority of treatment for tumours of the salivary glands is surgery.

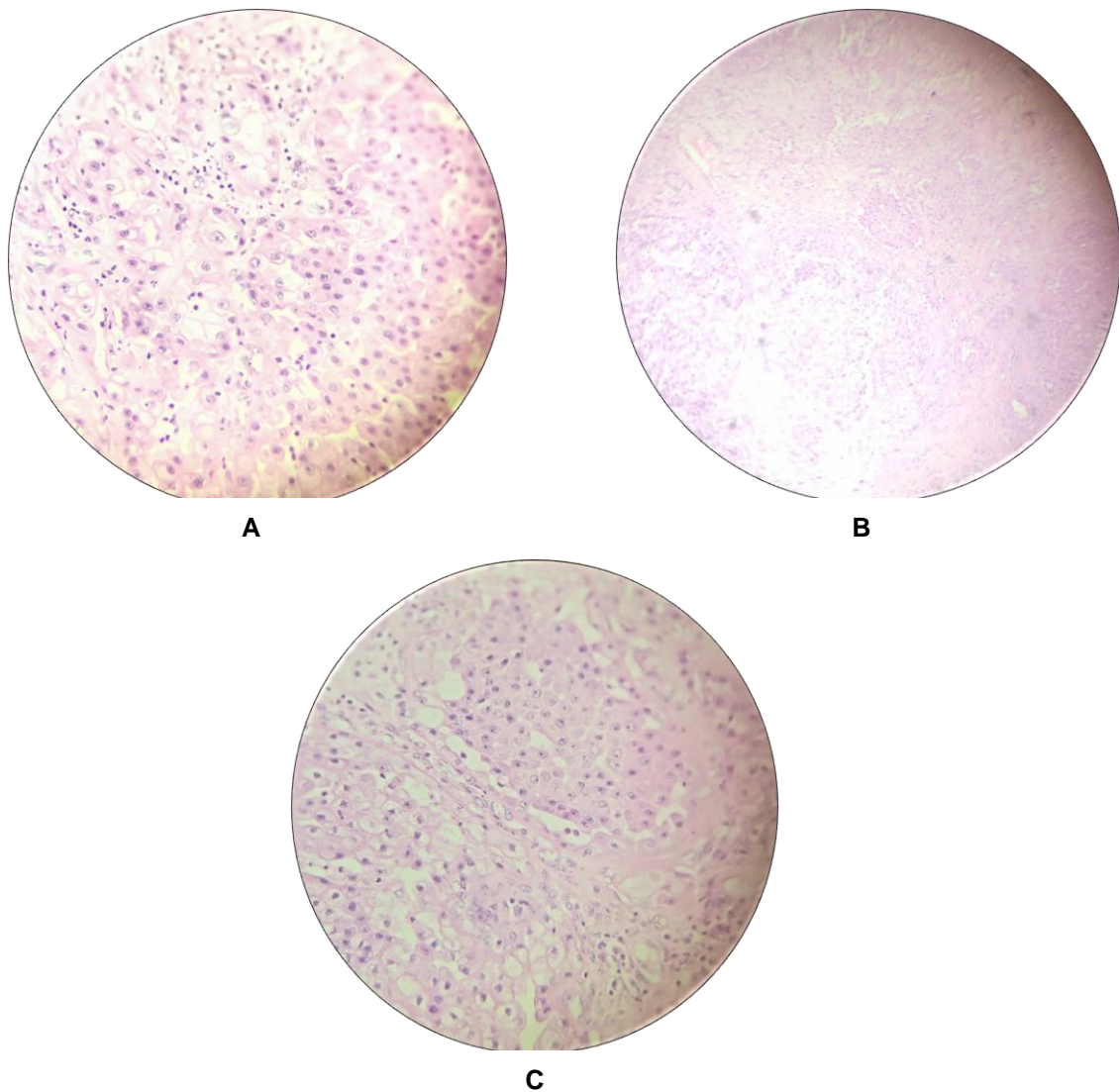


Fig. 7 (A,B,C). Histopathological slide picture of intermediate grade of mucoepidermoid carcinoma

Surgery alone can effectively cure benign tumours and early-stage low-grade malignancies, but postoperative radiation is necessary for more advanced, high-grade cancers that have metastasized to nearby lymph nodes. Chemotherapy's primary function is still palliative.

The standard diagnostic treatment for parotid gland tumours is superficial parotidectomy with facial nerve dissection and preservation. Total parotidectomy is the preferred surgery to obtain significant tumour clearance if the tumour affects the deep lobe of the parotid gland. This involves completely separating every branch of the facial nerve from the superficial lobe, then delivering the deep lobe from underneath the nerve. Radical parotidectomy, in which the facial nerve

is sacrificed, is only necessary if the tumour is enveloping or infiltrating the facial nerve. In these situations, there is frequently some degree of facial nerve paralysis present before surgery. Most frequently, an interposition graft from another nerve is used to restore the facial nerve after it has been removed.

We performed a total parotidectomy on our patient while preserving all facial nerve branches. Levels IB, II, III, IV, and VA should all be included in a selective neck dissection for parotid gland malignancy. High-grade malignancies and T3–4 tumours are also suitable for total parotidectomy with facial nerve preservation. Patients with salivary gland cancer who are at high risk of locoregional recurrence benefit from postoperative radiation [23].

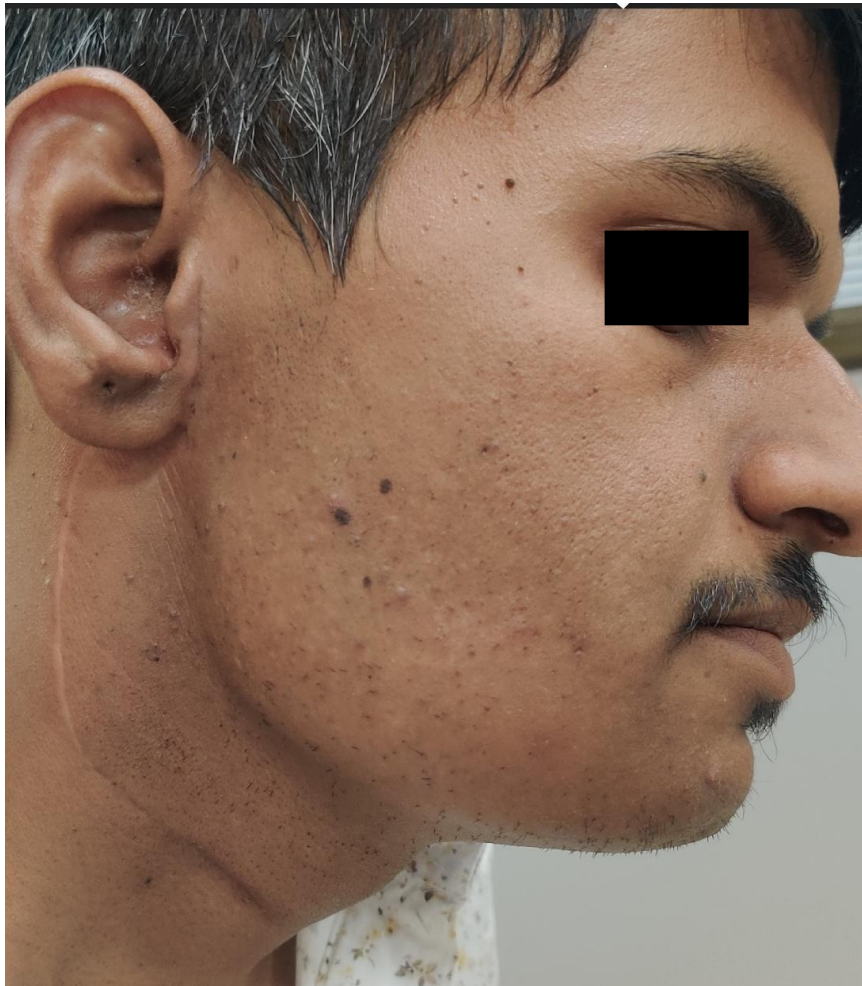

Fig. 8. Three months after completion of adjuvant treatment with well healed operated site

4. CONCLUSION

Because they are uncommon and necessitate a comprehensive examination by a multidisciplinary team of doctors, salivary gland tumours are best addressed in specialised head and neck clinics. Since surgery can be used for both diagnostic and therapeutic objectives, it serves as the cornerstone of their management. The surgical planning and preoperative counselling are the most crucial steps. To evaluate the predicted amount of resection and the potential risk to the facial nerve, large or deep parotid lobe tumours, as well as those believed to be malignant, should be scanned, ideally using MRI. The facial nerve is carefully identified and preserved during the entire surgical procedure to remove a parotid tumour. In cases of clinically N0 salivary gland cancer, elective selective neck dissection is advised when the main tumour displays high-risk characteristics. Postoperative radiation is

beneficial for tumours that run the risk of locoregional recurrence, on a similar note. Chemotherapy's function has not yet been fully established.

CONSENT

As per international standard or university standard, patient(s) written consent has been collected and preserved by the author(s).

ETHICAL APPROVAL

As per international standard or university standard written ethical approval has been collected and preserved by the author(s).

CONFLICT OF INTEREST

The author (s) declares no potential conflicts of interest with respect to the research, authorship, and/or publication of this paper.

REFERENCES

1. McHugh JB, Visscher DW, Barnes EL. Update on selected salivary gland neoplasms. *Arch Pathol Lab Med.* 2009;133:1763-1774.
2. Védrine PO, Coffinet L, Temam S, Montagne K, Lapeyre M, Oberlin O, Orbach D, Simon C, Sommelet D. Mucoepidermoid carcinoma of salivary glands in the pediatric age group: 18 clinical cases, including 11 second malignant neoplasms. *Head Neck.* 2006;28:827–833.
3. Batsakis JG. Salivary gland neoplasia: An outcome of modified morphogenesis and cytodifferentiation. *Oral Surg Oral Med Oral Pathol.* 1980;49:229-232.
4. Stewart FW, Foote FW Jr, Becker WF. Muco-epidermoid tumors of salivary glands. *Ann Surg.* 1945;122:820-844
5. Goode RK, Auclair PL, Ellis GL. Mucoepidermoid carcinoma of the major salivary glands: Clinical and histopathologic analysis of 234 cases with evaluation of grading criteria. *Cancer.* 1998;82:1217-1224.
6. Brandwein MS, Ivanov K, Wallace DI, et al. Mucoepidermoid carcinoma: A clinicopathologic study of 80 patients with special reference to histological grading. *Am J Surg Pathol.* 2001;25:835-845.
7. Nascimento AG, Amaral LP, Prado LA, Kligerman J, Silveira TR. Mucoepidermoid carcinoma of salivary glands: A clinicopathologic study of 46 cases. *Head Neck Surg.* 1986;8:409-417.
8. Califano L, Zupi A, Massari PS, Giardino C. Indication for neck dissection in carcinoma of the parotid gland: Our experience on 39 cases. *Int Surg.* 1993;78:347-349.
9. Luna MA. Salivary mucoepidermoid carcinoma: Revisited. *Adv Anat Pathol.* 2006;13:293-307.
10. Tirado Y, Williams HD, Hanna EY, Kaye FJ, Batsakis JG, El-Naggar AK. CRTC1/MAML2 fusion transcript in high grade mucoepidermoid carcinomas of salivary and thyroid glands and Warthin's tumors: Implications for histogenesis and biologic behavior. *Genes Chromosomes Cancer.* 2007;46: 708-715.
11. Cheuk W, Chan JK. Advances in salivary gland pathology. *Histopathology.* 2007;51: 1-20.
12. Spiro RH, Huvos AG, Berk R, Strong EW. Mucoepidermoid carcinoma of salivary gland origin: A clinicopathologic study of 367 cases. *Am J Surg.* 1978;136:461-468.
13. Byrd SA, Spector ME, Carey T, Bradford CR, McHugh JB. Predictors of recurrence and survival for head and neck mucoepidermoid carcinoma. *Otolaryngol. Neck Surg.* 2013;149:402–408.
14. Gilbert J, Li Y, Pinto HA, et al. Phase II trial of taxol in salivary gland malignancies (E1394): A trial of the Eastern Cooperative Oncology Group. *Head Neck.* 2006;28:197-204.
15. Horn-Ross PL, Morrow M, Ljung BM. "Diet and the risk of salivary gland cancer." *American Journal of Epidemiology.* 1997;146(2):171–176.
16. Swanson GM, Burns PB. "Cancers of the salivary gland: workplace risks among women and men." *Annals of Epidemiology.* 1997;7(6):369–374.
17. Dong C, Hemminki K. "Second primary neoplasms among 53 159 haematolymphoproliferative malignancy patients in Sweden, 1958–1996: A search for common mechanisms." *British Journal of Cancer.* 2001;85(7):997–1005.
18. Orell SR. "Diagnostic difficulties in the interpretation of fine needle aspirates of salivary gland lesions: The problem revisited." *Cytopathology.* 1995;6(5):285–300.
19. Li CZ, Sun MY, Zhang XH, Luo XL, Sun WB. Analysis of postoperative survival rates of mucoepidermoid carcinoma in salivary gland. *Zhonghua Kou Qiang Yi Xue Za Zhi.* 2006;41:709–712.
20. Ali S, Sarhan M, Palmer FL, Witcher M, Shah JP, Patel SG, Ganly I. Cause-specific mortality in patients with mucoepidermoid carcinoma of the major salivary glands. *Ann. Surg. Oncol.* 2013;20:2396–2404.
21. Chen M, Roman SA, Sosa JA, Judson BL. Histologic grade as prognostic indicator for mucoepidermoid carcinoma: A population-level analysis of 2400 patients. *Head Neck.* 2013;36:158–163.
22. Agulnik M, McGann C, Mittal B, Gordon S, Epstein J. "Management of salivary gland malignancies: current and developing

- therapies. *Oncology Reviews*. 2008;2(2): 86– 94.
23. Armstrong JG, Harrison LB, Spiro RH, Fass DE, Strong EW, Fuks ZY. "Malignant tumors of major salivary gland origin: A matched-pair analysis of the role of combined surgery and postoperative radiotherapy. *Archives of Otolaryngology*. 1990;116(3):290–293.

© 2023 Goyal et al.; This is an Open Access article distributed under the terms of the Creative Commons Attribution License (<http://creativecommons.org/licenses/by/4.0>), which permits unrestricted use, distribution, and reproduction in any medium, provided the original work is properly cited.

Peer-review history:
The peer review history for this paper can be accessed here:
<https://www.sdiarticle5.com/review-history/98053>