



# Isolated Case Presentation on Phacolytic Uveitis

**Z. Hazil <sup>a\*</sup>, A. Krichen <sup>a</sup>, N. Tebay <sup>a</sup>, I. Hasnaoui <sup>a</sup>,  
S. Hassina <sup>a</sup>, Y. Akannour <sup>a</sup>, L. Seghini <sup>a</sup>, Z. Hajji <sup>a</sup>,  
B. Ouazzani <sup>a</sup> and E. Abdallah <sup>a</sup>**

<sup>a</sup> *Department of Ophthalmology B, Rabat Specialty Hospital, CHU ibn Sina, Mohammed V Souissi University, Rabat, Morocco.*

## **Authors' contributions**

*This work was carried out in collaboration among all authors. All authors read and approved the final manuscript.*

## **Article Information**

DOI: 10.9734/OR/2024/v19i3420

## **Open Peer Review History:**

This journal follows the Advanced Open Peer Review policy. Identity of the Reviewers, Editor(s) and additional Reviewers, peer review comments, different versions of the manuscript, comments of the editors, etc are available here: <https://www.sdiarticle5.com/review-history/115349>

## **Clinical Image**

**Received: 27/01/2024**

**Accepted: 02/04/2024**

**Published: 13/04/2024**

## **1. CLINICAL IMAGE**

We report the case of a 70-year-old diabetic and hypertensive patient on treatment who presented with progressive loss of visual acuity in both eyes, complicated by redness and slight pain in the left eye, Ophthalmological examination revealed visual acuity in the left eye with finger movements, conjunctival hyperhemia, cornea with mixed keratic precipitates, protein and cellular Tyndall rated at two crosses in the anterior chamber, with the presence of a hypopyon blade at an irregular upper level, cyclitic membrane with crystalline masses opposite the pupillary area, dense cataract on

the lens (Figs. 1,2,3), ocular tone at 19 mmhg, the rest of the examination inaccessible, examination of the Adelphe eye was normal, apart from a posterior subcapsular cortico-nuclear cataract, and additional B-mode ocular ultrasound to explore the posterior pole of the left eye was normal, apart from a posterior vitreous detachment. The patient was put on local and systemic corticosteroids, and the patient underwent phacoemulsification of his cataract after mild control of ocular inflammation [1-3].

Phacoantigenic uveitis, also known as phacolytic uveitis, is caused by the release of soluble

\*Corresponding author: E-mail: zahira.hazil@gmail.com;

crystalline proteins through an intact capsule, following lysis of crystalline fibers in hypermature or rapidly progressing cataracts.

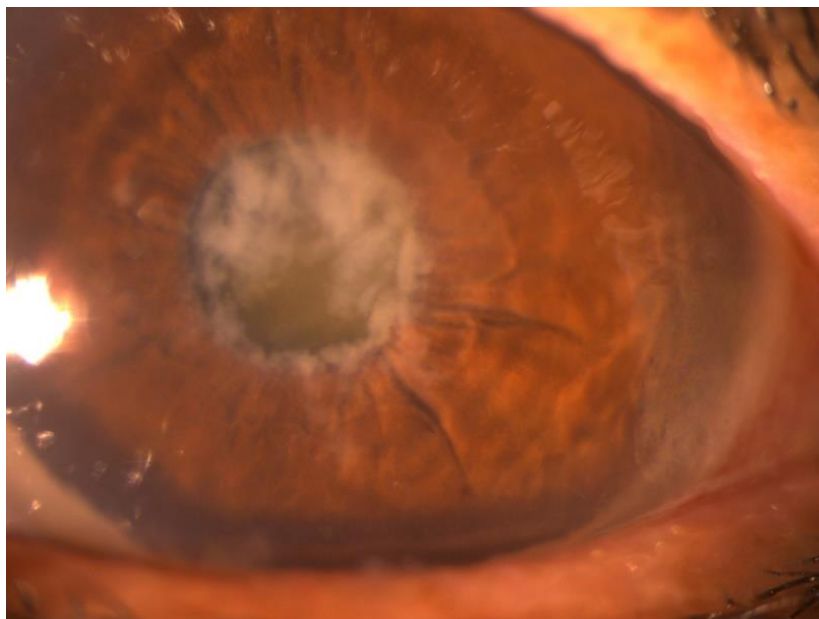
Phacolytic uveitis may manifest as any combination of conjunctival/episcleral hyperemia, corneal edema, endothelial keratic precipitates, aqueous flare, iritis, iridal adhesions, pupillary

miosis, uveal cyst formation, ectropion uvea, and/or decreased intraocular pressure (IOP).

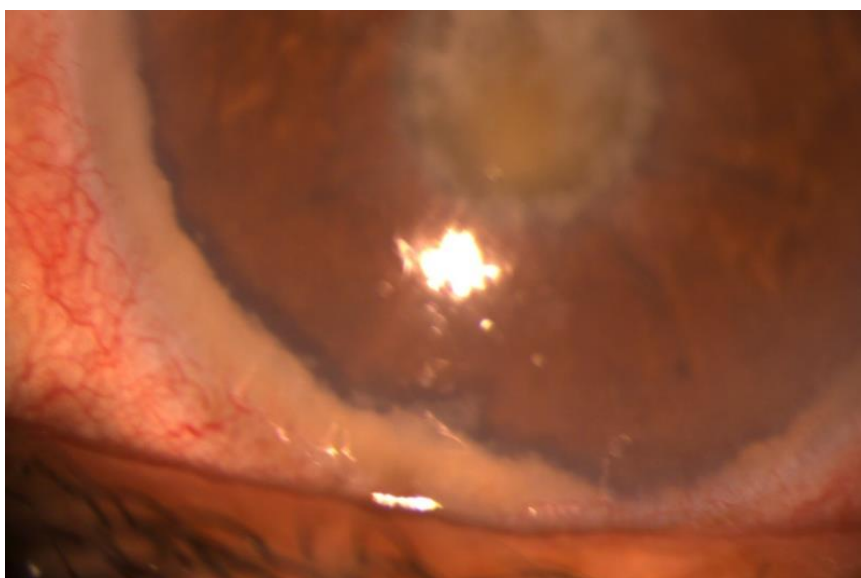
Treatment is based on the early introduction of steroidal anti-inflammatory agents, using a combination of topical and systemic routes, to reduce the likelihood of secondary inflammatory complications and avoid affecting the prognosis of cataract surgery.



**Fig. 1. Slit lamp image showing an inflammatory tyndall in the anterior chamber**



**Fig. 2. Slit lamp image showing crystalline masses with a cyclitic membrane**



**Fig. 3. Slit lamp image showing a hypopyon in the anterior chamber**

#### **CONSENT**

As per international standards or university standards, patient(s) written consent has been collected and preserved by the author(s).

#### **ETHICAL APPROVAL**

As per international standards or university standards written ethical approval has been collected and preserved by the author(s).

#### **COMPETING INTERESTS**

Authors have declared that no competing interests exist.

#### **REFERENCES**

1. Van Der Woerd A. Lens-induced uveitis. *Veterinary Ophthalmology*. 2000 Dec;3(4): 227-34.
2. Filipe JC, Palmares J, Delgado LS, Lopes JM, Borges J, Castro-Correia J. Phacolytic glaucoma and lens-induced uveitis. *International Ophthalmology*. 1993 Oct;17: 289-93.
3. Forster DJ. Phacoantigenic uveitis. *Ophthalmology Text Book*. 2004;2: 1201-4.

© Copyright (2024): Author(s). The licensee is the journal publisher. This is an Open Access article distributed under the terms of the Creative Commons Attribution License (<http://creativecommons.org/licenses/by/4.0>), which permits unrestricted use, distribution, and reproduction in any medium, provided the original work is properly cited.

*Peer-review history:*  
*The peer review history for this paper can be accessed here:*  
<https://www.sdiarticle5.com/review-history/115349>