



The Effect of Percutaneous Vertebroplasty in Glucocorticoid Induced Osteoporotic Vertebral Compression Fractures: A Case Report

Jae Hyung Ryu ^{a*}, Yu Jin Kim ^a and Sang Sik Choi ^a

^a *Department of Anesthesiology and Pain Medicine, Korea University Guro Hospital, Korea University College of Medicine, Gurodong-ro 148, Guro-gu, Seoul-08308, Republic of Korea.*

Authors' contributions

This work was carried out in collaboration among all authors. All authors read and approved the final manuscript.

Article Information

DOI: 10.9734/JAMMR/2024/v36i15348

Open Peer Review History:

This journal follows the Advanced Open Peer Review policy. Identity of the Reviewers, Editor(s) and additional Reviewers, peer review comments, different versions of the manuscript, comments of the editors, etc are available here:

<https://www.sdiarticle5.com/review-history/111790>

Case Study

Received: 07/11/2023

Accepted: 12/01/2024

Published: 13/01/2024

ABSTRACT

A 73-year-old woman with secondary adrenal insufficiency, who discontinued denosumab injection 9 months ago, presented with severe back pain. She was already diagnosed with an acute L1 compression fracture refractory to a month-long conservative treatment. Consequently, L1 percutaneous vertebroplasty (PVP) was performed, but the patient continued to complain of persistent lower back pain. Subsequent magnetic resonance imaging (MRI) revealed acute compression fractures at L2 and L5 vertebral body. After additional PVPs at L2 and L5, the patient experienced a dramatic reduction in pain. However, three weeks later, a new compression fracture occurred at L3, and she is currently undergoing conservative treatment. Percutaneous vertebral augmentation (PVA) is a safe and immediately effective treatment for glucocorticoid-induced osteoporosis (GIOP)-related osteoporotic vertebral compression fracture (OVCF) when pain is not controlled by conservative treatment. Abrupt discontinuation of prolonged Denosumab treatment can lead to rebound fractures; therefore, transitioning appropriately according to guidelines is recommended.

*Corresponding author: E-mail: jakezzzz@naver.com, jakezzzz526@gmail.com;

Keywords: Percutaneous vertebroplasty; osteoporotic vertebral compression fractures; secondary adrenal insufficiency; glucocorticoid-induced osteoporosis; discontinuation of denosumab; rebound fractures;

1. INTRODUCTION

Osteoporotic vertebral compression fractures (OVCFs) occur in approximately 1.4 million cases worldwide [1], and the causes of osteoporosis are diverse. Among them, glucocorticoid-induced osteoporosis (GIOP) is known to be the most common cause of drug-induced secondary osteoporosis. Currently, guidelines may vary, but there is consensus on the crucial initial assessment of fracture risk to prevent GIOP-related fractures, and initiating both pharmacological and non-pharmacological treatments based on this evaluation is recommended [2,3]. However, in the case of OVCF induced by GIOP, there is ongoing debate regarding whether to pursue conservative treatment or percutaneous vertebral augmentation (PVA). In this context, we have encountered a case where a patient at a high risk of fractures due to GIOP experienced consecutive multiple vertebral fractures over 2 months, starting from the 9th month after

voluntarily cessation of denosumab injection. We would like to report this case along with a literature review.

2. CASE REPORT

A 73-year-old woman presented to Guro Korea University Medical Center with severe back pain. She had a medical history of secondary adrenal insufficiency and percutaneous vertebroplasty (PVP) for an L4 compression fracture in August of the year 2022. In mid-July of the year 2023, she experienced abrupt lower back pain after lifting a heavy object, and an L-spine magnetic resonance imaging (MRI) revealed an acute L1 compression fracture (Fig. 1). Despite receiving conservative treatments, including medication, bracing, and absolute bed rest (ABR), during a month-long hospitalization at another facility, there was no improvement in pain. Consequently, she presented our clinic seeking further treatment on August 23rd.

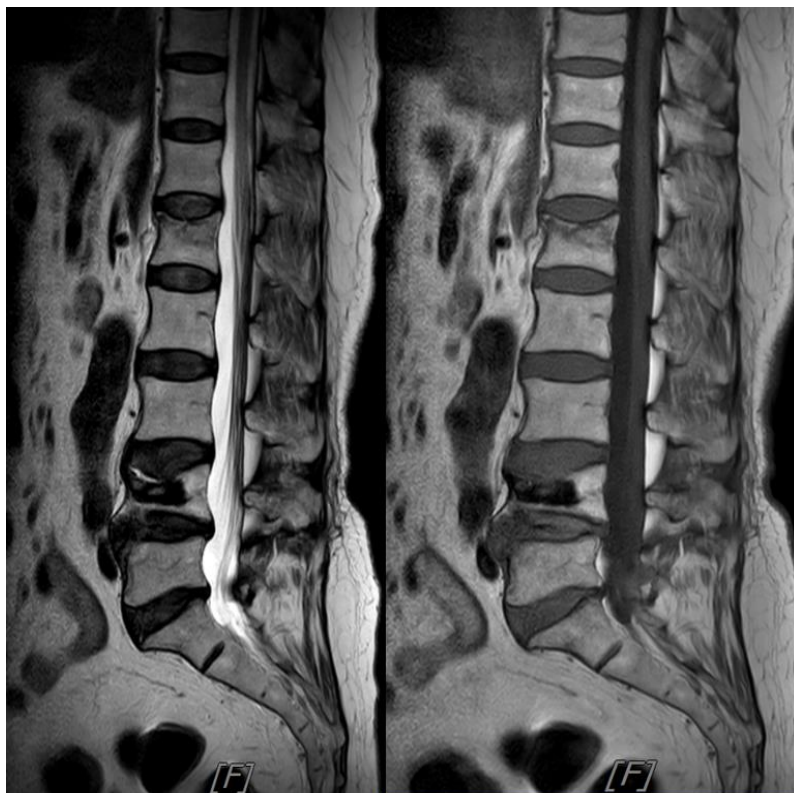


Fig. 1. L-spine MRI images taken at another facility. Parasagittal T2 & T1-weighted images show acute L1 vertebral body compression fracture

The patient complained of localized pain in the lower back without leg numbness, with a visual analogue scale (VAS) pain score of 7/10, aggravated by movement. Physical examination revealed tenderness at the L1 spinous process, while other neurological exams showed negative findings. Additionally, her recent bone mineral density (BMD) indicated a T-score of -3.8, indicating severe osteoporosis. Consequently, the patient was diagnosed with an osteoporotic compression fracture of L1 and hospitalized for pain control. On August 28th, continuous epidural block was performed, followed by PVP on August 30th. The patient received her last Denosumab injection on October 27th, 2022, and to prevent rebound fractures due to the absence of additional osteoporosis treatment, zoledronate was administered.

The day after L1 PVP, the patient still complained of persistent back pain. Upon reassessment, tenderness was newly noted at the spinous processes of L2 and L5. And in the x-ray performed at the time of hospitalization on August 27th, we found that the L2 vertebral body was slightly lowered (Fig. 2). Considering her bedridden state since the end of July without any

specific trauma, it was concluded that new acute compression fractures occurred spontaneously between July 31st and August 27th.

A new MRI was conducted on September 3rd (Fig. 3). The MRI revealed compression fractures with bone marrow edema that is suggestive of recent fractures at L2 and is a suspicion of compression fracture at L5. Subsequently, on September 4th, additional PVPs were performed at L2 and L5 (Fig. 4). Fortunately, the patient experienced a dramatic reduction in motion-related pain from VAS 7 to 2-3 points without significant complications, and she was discharged on September 6th.

On the outpatient visit on September 27th, the patient reported well-controlled pain with a VAS score of 2. However, on the way home, she experienced severe lower back pain again and promptly visited the Emergency Room. Upon examination with L-spine computed tomography, a newly noted compression fracture at the L3 vertebral body was observed (Fig. 5). Currently, the patient is undergoing conservative treatment (medication, back brace) as requested.

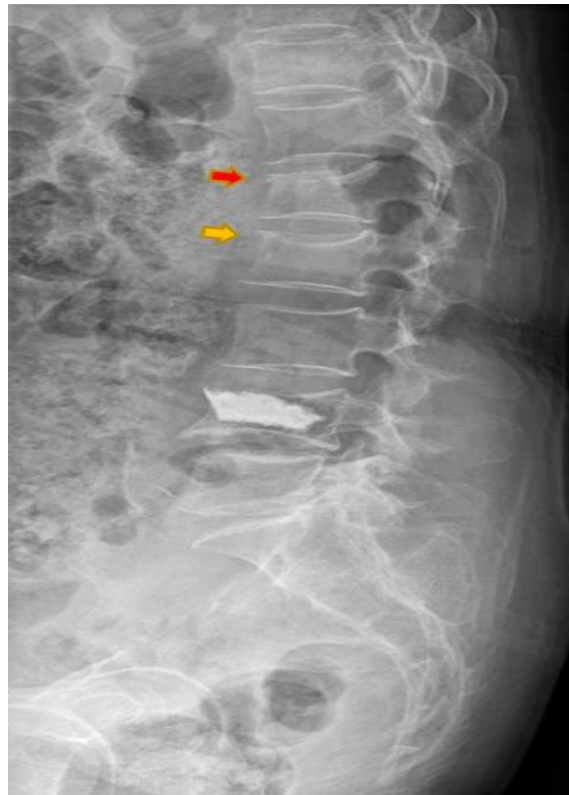

Fig. 2. Lateral view of plain radiograph. The upper endplate of not only L1 (Red arrow) but also L2 vertebral body (Yellow arrow) was slightly lowered

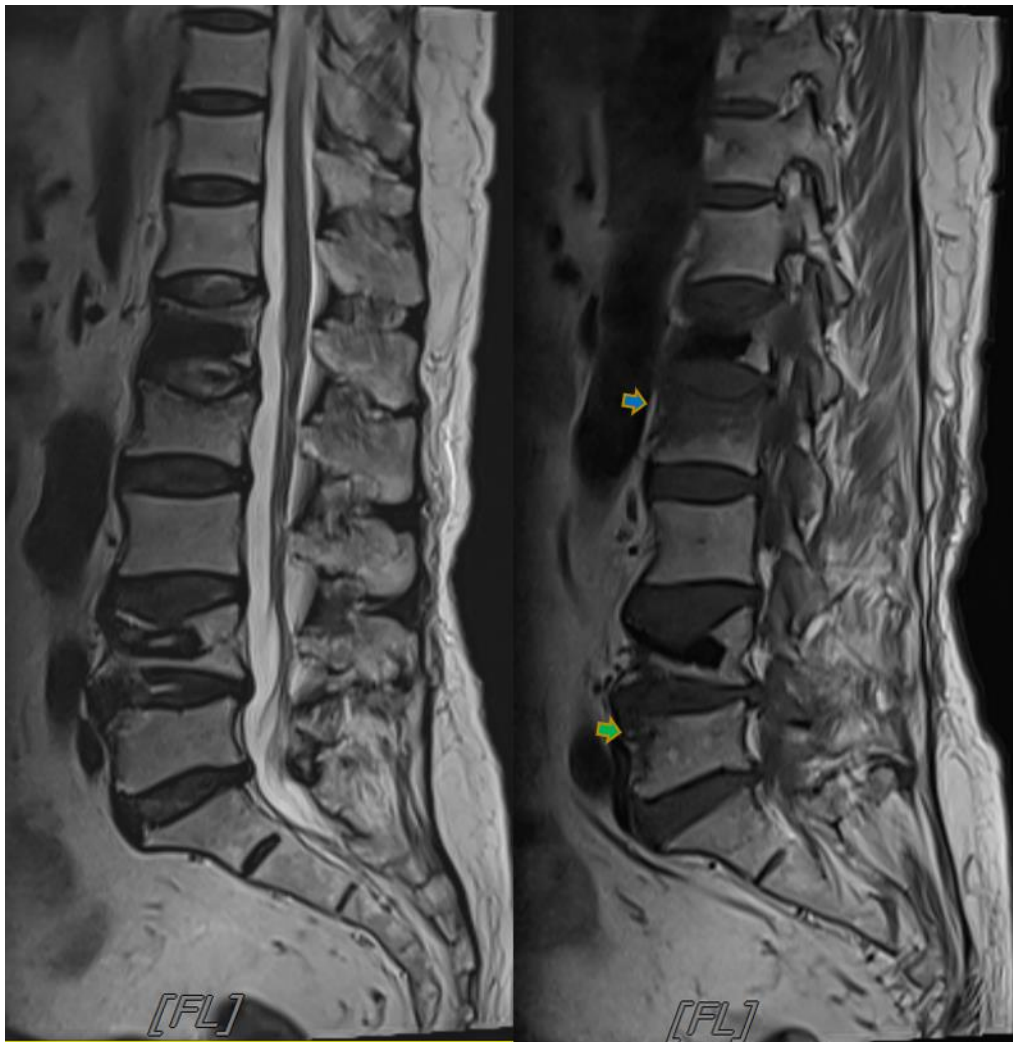

Fig. 3. New L-spine MRI taken on September 3rd. A parasagittal T2 & T1-weighted images show a compression fracture with bone marrow edema, suggestive of recent fracture, at L2 vertebra (Blue arrow) and suspicion of compression fracture at anterior portion of L5 vertebra (Green arrow)

3. DISCUSSION

Secondary osteoporosis is induced by various other conditions. Secondary osteoporosis can be broadly categorized into lifestyle changes, genetic diseases, endocrine disorders, gastrointestinal disorders, hematological disorders, neurological and musculoskeletal factors, rheumatologic and autoimmune diseases, and other causes [4]. Among them, Glucocorticoid-induced osteoporosis (GIOP) is the most common drug-induced cause of secondary osteoporosis. The mechanism of GIOP involves both bone resorption and formation. Glucocorticoids stimulate osteoclastogenesis and bone resorption by increasing the expression of Nuclear factor-

kappa B ligand and colony-stimulating factor-1 while decreasing the expression of osteoprotegerin [5]. Furthermore, glucocorticoids inhibit osteoblastogenesis and the function of osteoblasts, induce apoptosis of mature osteoclasts, and increase adipogenesis, leading to a negative impact on bone formation [5]. Additionally, they have an indirect impact on bone resorption by inducing changes in calcium homeostasis and Vitamin D metabolism [5]. Glucocorticoids may also lead to hypogonadism, and consequently, estrogen or androgen deficiency can contribute to bone loss [5].

In the end, the primary concern regarding GIOP revolves around the heightened risk of fractures. Interestingly, it has been documented that 30-

50% of individuals utilizing glucocorticoids over an extended period undergo fractures at some point in their lives [6]. A 2002 Meta-analysis revealed that oral corticosteroid treatment exceeding 5mg/day leads to diminished BMD and an escalated risk of fractures, particularly affecting the vertebral and hip regions [7]. Furthermore, even when BMD is comparable, GIOP patients exhibit a significantly higher occurrence of vertebral fractures compared to those with postmenopausal osteoporosis [7]. These observations suggest that glucocorticoid

therapy inadvertently compromises both the quantity and quality of bone. Moreover, glucocorticoids have a direct catabolic effect on muscles, resulting in the loss of muscle mass and strength. This condition increases the risk of falls and fractures [8]. Fortunately, if glucocorticoid therapy is discontinued, the fracture risk significantly decreases to baseline within a year [6]. Therefore, the most effective way to prevent GIOP-related fracture is to discontinue glucocorticoid use. However, there are patients for whom this may not be feasible.

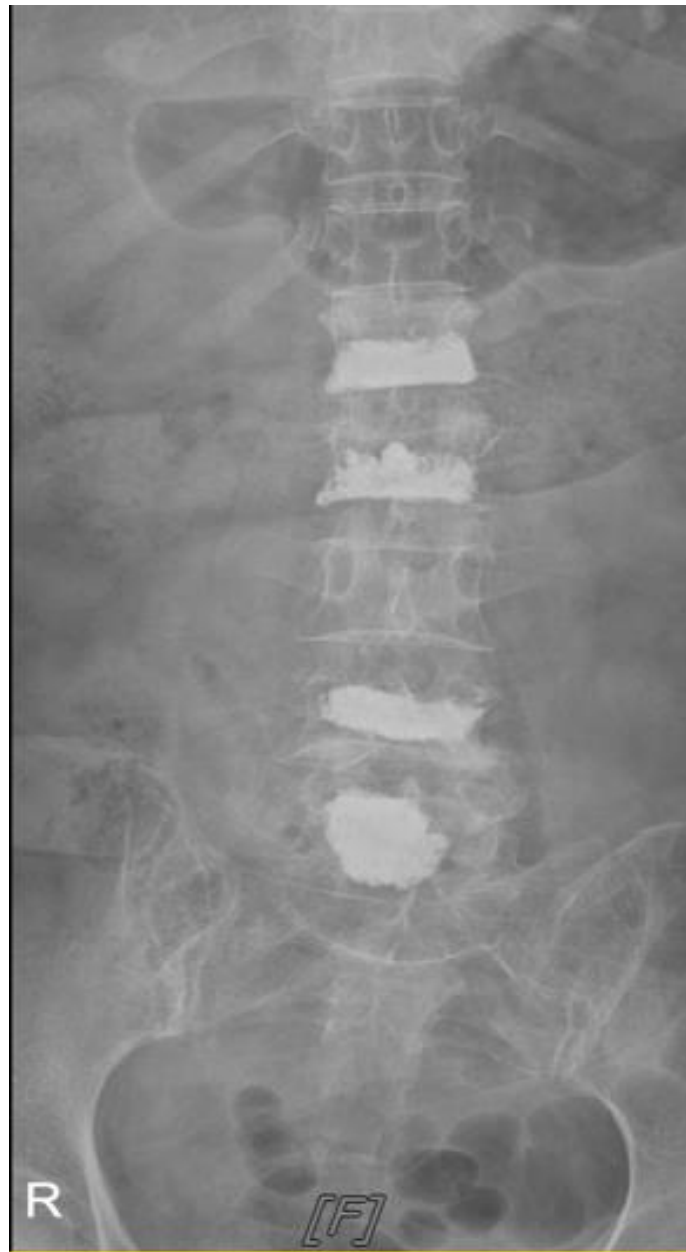

Fig. 4. Follow up anteroposterior view of plain radiograph. Post-vertebroplasty state at L1, L2, L4 and L5

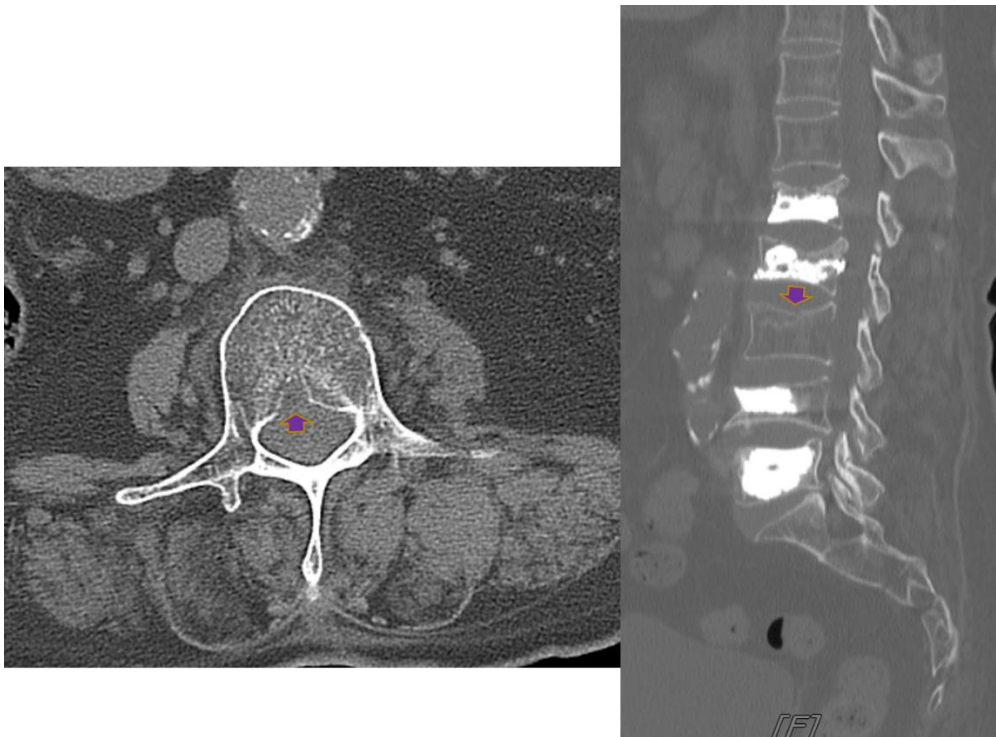


Fig. 5. Axial and parasagittal computed tomography images. Newly noted compression fracture at L3 vertebral body (Purple arrow)

Therefore, it is crucial to proactively prevent GIOP. According to the guidelines from the American College of Rheumatology, an initial assessment of fracture risk should be conducted within the first 6 months of starting glucocorticoid treatment, utilizing tools like FRAX and BMD testing [2]. All individuals taking prednisone at a dose of ≥ 2.5 mg/day for more than 3 months should initiate preventive treatment for osteoporosis [2]. It is highly recommended to optimize calcium intake (1000-1200 mg/day) and vitamin D intake (600-800 IU/day), adopt a balanced diet, maintain weight within the recommended range, quit smoking, engage in regular weight-bearing or resistance training exercises, and limit alcohol intake to 1-2 alcoholic beverages per day [2]. For adults aged ≥ 40 years at high risk of fracture, oral bisphosphonates can be used as the first-line therapy [2]. If oral bisphosphonates are not suitable due to patient preference or intolerance, consider IV bisphosphonates, teriparatide, denosumab, or raloxifene [2].

Despite the efforts made for GIOP prevention, instances of GIOP and GIOP-induced vertebral fractures can still occur. In such cases, conservative treatments including short-term bed rest, medication for pain control, bracing, and physical therapy, can be prioritized with the goal

of pain control and rehabilitation [9]. However, reducing mobilization to alleviate pain in OVCF patients may lead to various complications such as bone loss, muscle weakness, deep vein thrombosis, orthostatic hypotension, social isolation, weakening of respiratory muscles, decreased lung capacity, and respiratory infections [10].

Despite the controversies regarding the efficacy of PVA [11], a position statement from multiple US Societies suggested that PVA is an appropriate treatment for painful vertebral fractures refractory to conservative treatments [10]. Indeed, in 2004, Lee et al. reported that PVA provides immediate pain reduction, enables early ambulation, and reinforces the vertebral body with compression fractures [12]. According to Yang et al. in 2016, PVA-treated patients had fewer complications, higher satisfaction, and better pain control than those with conservative treatment during the one-year follow-up. [13]. However, there can be complications with PVA, such as a temporary increase in pain after the procedure, transient arterial hypotension, an increased risk of new fractures, potential cement leakage into the disc/epidural space/paravertebral veins, as well as the possibility of infection and bleeding [14].

In this case, despite approximately one month of conservative treatment, the patient's pain remained uncontrolled, leading to hospitalization. Following the multi-level vertebroplasty performed at our clinic, the patient experienced a rapid reduction in pain to around VAS 2-3/10 without any specific complications. This suggests that PVP is an effective, safe, and immediately pain-relieving treatment for OVCF cases where pain is unresponsive to conservative therapy, showing higher treatment satisfaction.

Also, patient received Denosumab consistently since the osteoporosis diagnosis in February 2020, with the last injection on October 27, 2022 and the patient had not undergone any further osteoporosis treatment since then. Utilizing the FRAX, the calculated 10-year risk for major osteoporotic fracture was 35%, and the 10-year probability of hip fracture was 13%, categorizing the patient as at very high risk. In such cases, following the guidelines of the European Calcified Tissue Society, one should consider either continuing Denosumab injections for up to 10 years or transitioning to zoledronate or oral bisphosphonates with monitoring of bone turnover markers every 6 months after the last injection [15]. Indeed, despite maintaining a T-score of approximately -2.7 in the BMD measurements in 2021 and 2022, the BMD measured in July 2023 showed a T-score of -3.7. Therefore, we considered that consecutive OVCF occurred due to rebound fractures following the discontinuation of Denosumab.

4. CONCLUSION

PVA is a safe and immediately effective treatment for GIOP-induced OVCF when pain is not controlled by conservative treatment. Abrupt discontinuation of prolonged Denosumab treatment can lead to rebound fractures; therefore, transitioning appropriately according to guidelines is recommended.

CONSENT

Written consent obtained from the patient has been collected and preserved by the authors.

ETHICAL APPROVAL

As per international standard or university standards written ethical approval has been collected and preserved by the author(s).

COMPETING INTERESTS

Authors have declared that no competing interests exist.

REFERENCES

1. Johnell O, Kanis JA. An estimate of the worldwide prevalence and disability associated with osteoporotic fractures. *Osteoporos Int.* 2006;17(12):1726-33. DOI:10.1007/s00198-006-0172-4. Epub 2006 Sep 16. PMID: 16983459.
2. Buckley L, Guyatt G, Fink HA, Cannon M, Grossman J, Hansen KE et al. 2017 American College of Rheumatology Guideline for the Prevention and Treatment of Glucocorticoid-Induced Osteoporosis. *Arthritis Rheumatol.* 2017 ;69(8):1521-1537. DOI: 10.1002/art.40137. Epub 2017 Jun 6. Erratum in: *Arthritis Rheumatol.* 2017 Nov;69(11):2246. PMID: 28585373.
3. Laurent MR, Goemaere S, Verroken C, Bergmann P, Body JJ, Bruyère O, Cavalier E et al. Prevention and Treatment of Glucocorticoid-Induced Osteoporosis in Adults: Consensus Recommendations From the Belgian Bone Club. *Front Endocrinol (Lausanne).* 2022;13:908727. DOI: 10.3389/fendo.2022.908727. PMID: 35757436; PMCID: PMC9219603.
4. Sözen T, Özişik L, Başaran NÇ. An overview and management of osteoporosis. *Eur J Rheumatol.* 2017; 4(1):46-56. DOI: 10.5152/eurjrheum.2016.048. Epub 2016 Dec 30. PMID: 28293453; PMCID: PMC5335887.
5. Canalis E. Mechanisms of glucocorticoid-induced osteoporosis. *Curr Opin Rheumatol.* 2003;15(4):454-7. DOI:10.1097/00002281-200307000-00013. PMID: 12819474.
6. Weinstein RS. Clinical practice. Glucocorticoid-induced bone disease. *N Engl J Med.* 2011;365(1):62-70. DOI:10.1056/NEJMc1012926
7. van Staa TP, Leufkens HG, Cooper C. The epidemiology of corticosteroid-induced osteoporosis: a meta-analysis. *Osteoporos Int.* 2002;13(10):777-87. DOI:10.1007/s001980200108. PMID: 12378366.
8. Pereira RMR, de Carvalho JF, de Carvalho JF. Glucocorticoid-induced myopathy. *Joint Bone Spine.* 2011.

- DOI: 10.1016/j.jbspin.2010.02.025
9. Garg B, Dixit V, Batra S, Malhotra R, Sharan A. Non-surgical management of acute osteoporotic vertebral compression fracture: A review. *J Clin Orthop Trauma*. 2017;8(2):131-138. DOI:10.1016/j.jcot.2017.02.001. Epub 2017 Feb 7. PMID: 28720988; PMCID: PMC5498748.
10. Barr JD, Jensen ME, Hirsch JA, McGraw JK, Barr RM, Brook AL et al. Society of Interventional Radiology; American Association of Neurological Surgeons; Congress of Neurological Surgeons; American College of Radiology; American Society of Neuroradiology; American Society of Spine Radiology; Canadian Interventional Radiology Association; Society of Neurointerventional Surgery. Position statement on percutaneous vertebral augmentation: a consensus statement developed by the Society of Interventional Radiology (SIR), American Association of Neurological Surgeons (AANS) and the Congress of Neurological Surgeons (CNS), American College of Radiology (ACR), American Society of Neuroradiology (ASNR), American Society of Spine Radiology (ASSR), Canadian Interventional Radiology Association (CIRA), and the Society of NeuroInterventional Surgery (SNIS). *J Vasc Interv Radiol*. 2014 Feb;25(2):171-81. DOI:10.1016/j.jvir.2013.10.001. Epub 2013 Dec 8. PMID: 24325929.
11. Wong SPY, Mok CC. Management of glucocorticoid-related osteoporotic vertebral fracture. *Osteoporos Sarcopenia*. 2020;6(1):1-7. DOI: 10.1016/j.afos.2020.02.002. Epub 2020 Mar 3. PMID: 32226826; PMCID: PMC7093682.
12. Seung Myoung Lee, Chang Il Ju, Kyung Joon Lim. Percutaneous Vertebroplasty in Vertebral Body Compression Fracture. *Korean J Pain*. 2004;17(2):193-197
13. Er-Zhu Yang, Jian-Guang Xu, Gao-Zhong Huang, Wen-Zhen Xiao, Xiao-Kang Liu, Bing-Fang Zeng et al. Percutaneous Vertebroplasty Versus Conservative Treatment in Aged Patients With Acute Osteoporotic Vertebral Compression Fractures: A Prospective Randomized Controlled Clinical Study. *SPINE*. 2016; 41(8):653-660. DOI: 10.1097/BRS.0000000000001298
14. Al-Nakshabandi NA. Percutaneous vertebroplasty complications. *Ann Saudi Med*. 2011;31(3):294-7. DOI:10.4103/0256-4947.81542. PMID: 21623061; PMCID: PMC3119972.
15. Elena Tsourdi, M Carola Zillikens, Christian Meier, Jean-Jacques Body, Elena Gonzalez Rodriguez, Athanasios D Anastasilakis et al. Fracture Risk and Management of Discontinuation of Denosumab Therapy: A Systematic Review and Position Statement by ECTS, The Journal of Clinical Endocrinology & Metabolism. 2021;106(1):264–281. DOI:10.1210/clinem/dgaa756

© 2024 Ryu et al.; This is an Open Access article distributed under the terms of the Creative Commons Attribution License (<http://creativecommons.org/licenses/by/4.0>), which permits unrestricted use, distribution, and reproduction in any medium, provided the original work is properly cited.

Peer-review history:

The peer review history for this paper can be accessed here:

<https://www.sdiarticle5.com/review-history/111790>