

Epididymal Lymphangioma: An Atypical Case of Scrotal Swelling and Literature Review

S. N. Jatal ^{a++*}, Sudhir Jatal ^{b#}, Supriya Jatal ^{c†}
and Ganesh Swami ^{d‡}

^a Jatal Hospital and Research Centre, Latur, India.

^b Jatal Hospital and Research Centre, Latur, Tata Hospital, Mumbai, India.

^c Department of Clinical Nephrology, MGM Hospital and College, Navi Mumbai, India.

^d Department of Surgery, V.D. Govt. Medical College, Latur, India.

Authors' contributions

This work was carried out in collaboration among all authors. All authors read and approved the final manuscript.

Article Information

Open Peer Review History:

This journal follows the Advanced Open Peer Review policy. Identity of the Reviewers, Editor(s) and additional Reviewers, peer review comments, different versions of the manuscript, comments of the editors, etc are available here: <https://www.sdiarticle5.com/review-history/110612>

Case Study

Received: 13/10/2023

Accepted: 20/12/2023

Published: 29/12/2023

ABSTRACT

Lymphangioma of the epididymis is a rare condition that originates from the sequestration of lymphatic tissue, leading to a lack of normal communication with the lymphatic system. It consists of unilocular or multilocular lymphatic cysts lined by a single layer of endothelium. This benign tumor is typically identified at birth, during childhood, early adolescence, and occasionally in adulthood, with the most common locations being the head, neck, and axilla. Lymphangioma of the epididymis is exceptionally uncommon, with the first reported case by Thompson in 1936. Only six cases of cystic lymphangioma of the epididymis in adults have been documented in the English literature to date.

⁺⁺ M.S. F.I.C.S., FAIS, FIGES;

[#] Fellow in Colorectal Cancer;

[†] Assistant Professor;

[‡] Associate Professor;

*Corresponding author: Email: jatalhospital@gmail.com;

Here, we present an atypical case involving a 35-year-old male with a huge benign cystic lymphangioma of the right epididymis, manifesting as a painless inguinoscrotal cystic mass extending up to umbilicus. A complete surgical excision was performed, to minimize the risk of recurrence.

Keywords: Benign; cystic lymphangioma; epididymis.

1. INTRODUCTION

Lymphangiomas represent congenital lymphatic abnormalities primarily developing in the head and neck (75%), axilla (20%), and more rarely in other locations such as the liver, spleen, kidney, mediastinum, mesentery, retroperitoneum, inguinal region, and scrotum (5%). They account for approximately 26% of all benign vascular tumors in children, with 50% present at birth, and 90% emerging within the first two years of life. Inguinal and scrotal localization is exceptionally uncommon. Traditionally classified as capillary, cavernous, and cystic lymphangiomas. In adults may arise as primary benign cystic neoplasms or secondary to lymphatic obstruction associated with hernia surgery or trauma [1,2,3,4].

Microscopically, cysts in lymphangiomas are lined by flattened endothelial cells. The primary manifestation is a gradually painless mass. However, differentiating scrotal lymphangiomas from other scrotal pathologies, such as hernia, hydrocele, hematocele, varicocele, epididymal cysts, spermatic cord lipoma, teratoma, dermoid cyst, and epidermoid cyst, can be challenging due to similar clinical findings [2,5,4].

Ultrasonography with color doppler is a valuable diagnostic tool, and CT and MRI play crucial roles in cases with suspected pelvic or retroperitoneal extension. A definitive diagnosis is established through histopathological examination. Surgical treatment involves the preferred option of total excision of the mass, considered the gold standard in the pediatric age group. Total orchiectomy may be necessary for lesions inseparable from the testis and spermatic cord in adult [5,4,6].

2. CASE REPORT

On March 17, 2020, a 35-year-old male was admitted to our center complaining of a substantial right inguinoscrotal swelling that had gradually extended up to the umbilicus over the

last 2 years. There was no history of trauma or surgery in the past in the inguinoscrotal region. Upon physical examination, a painless right scrotal swelling was observed, extending through the right inguinal region up to the umbilicus. Scrotal ultrasonography revealed a thick-walled, massive solitary cystic lesion arising from the right testis, extending up to the umbilicus. The cystic lesion was filled with internal echoes and debris, and color Doppler study confirmed it as an avascular cystic lesion.

CT scans of the abdomen, pelvis, and scrotum showed a large unilocular cystic mass was found within the right scrotum, which extended to umbilicus, measuring 15x10 cm. The patient denied any history of trauma or surgery. The patient's general condition was healthy, and he had two children's. All laboratory investigations showing normal results. The ultrasonography and CT diagnosis confirmed a massive cystic lymphangioma of the right testis.

Surgical exploration through the right inguinal route revealed a surprisingly large cystic mass originating from the right testis and extending up to umbilicus, measuring 15x10 cm.

Right side Orchiectomy was performed along with the removal of the massive cyst. Upon gross examination, the huge mass weighed approximately 3 kg, and upon cutting the cystic lesion, 2 liters of dirty, yellowish-brown fluid were drained. Histopathological examination revealed a massive cystic mass filled with small cystic spaces lined by flattened endothelium and filled with lymph, suggesting a primary benign cystic lymphangioma of the epididymis (Figs. 1-10).

3. DISCUSSION

Cystic lymphangiomas can either be congenital tumors or arise secondary to factors such as post-inguinal hernia surgery or trauma. The majority of these lesions (90%) manifest during the first two years of childhood, and occurrences

in adulthood are uncommon. Typically, lymphangiomas primarily affect the head, neck, and axilla (95%), with a rarer (5%) occurrence in the liver, spleen, kidney, mesentery, and inguinoscrotal region. Traditionally, lymphangiomas are classified into three types: capillary, cavernous, and cystic lymphangiomas [2,5,4].

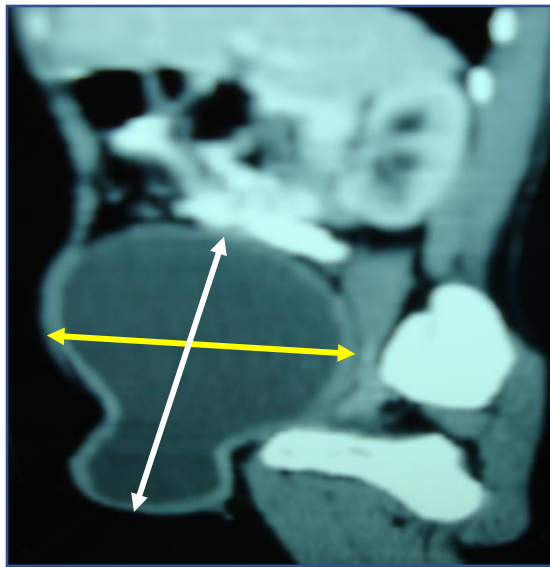


Fig. 1. CT pelvis and scrotum showed a large unilocular cystic lesion 15x10 cm with extrascrotal pelvis extension

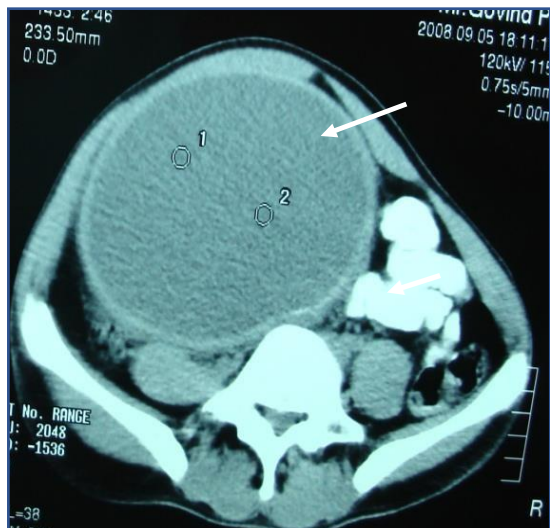

Fig. 2. CT pelvis showed a thick intra-abdominal cystic swelling

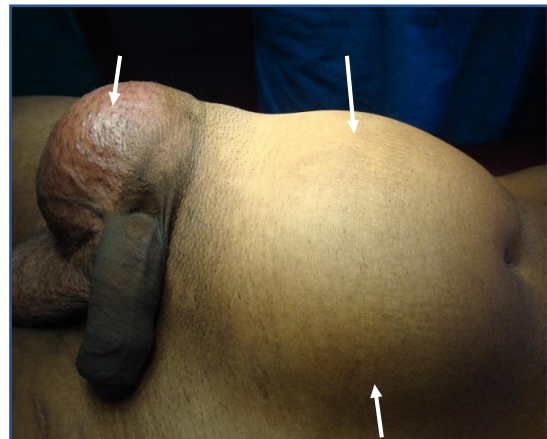

Fig. 3. Photographs showing inguinoscrotal swelling extending up to umbilicus

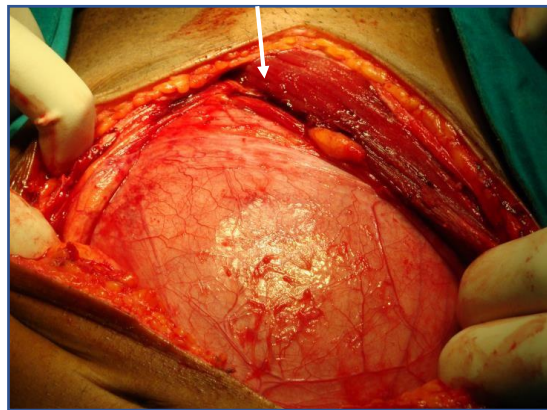


Fig. 4. Intraoperative photographs showing a huge cystic mass at right inguinal region

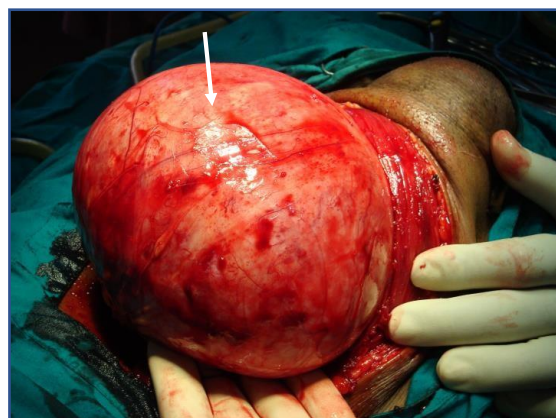

Fig. 5. Intraoperative photographs showing a huge cystic mass at right inguinal region

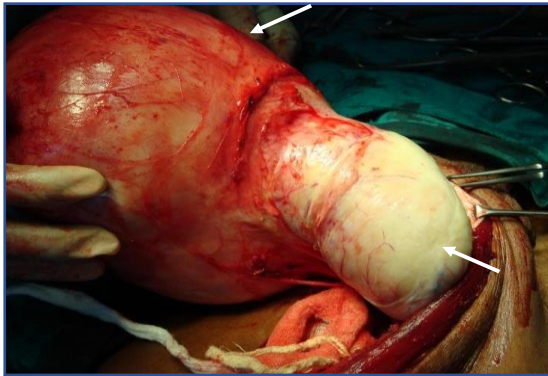


Fig. 6. Intraoperative photographs showing a huge cystic mass along with right testis

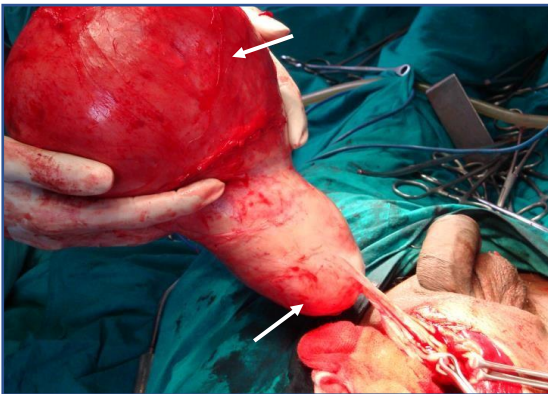


Fig. 7. Intraoperative photographs showing a huge cystic mass along with right testis

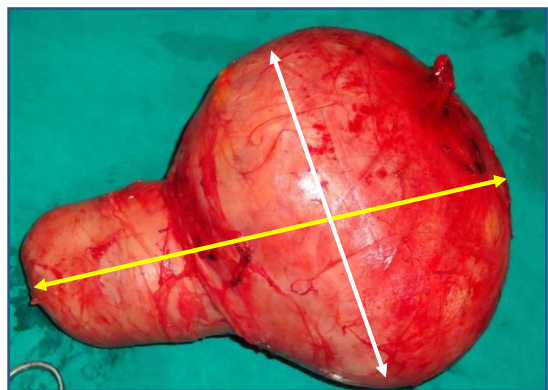


Fig. 8. Photograph showing well circumscribed solitary cystic mass of size 15x10 cm arising from right testis and weighing 3 kg

Intra-scrotal cystic lymphangiomas can be mistaken for other extra-testicular conditions, both common and uncommon, such as hydrocele, varicocele, hematocele, inguinal hernia, epididymal cyst, spermatocele, lipoma of

the spermatic cord, and hydatid of Morgagni. Patients with suspected cystic lesions that extend to the abdomen or pelvis can benefit from ultrasonography and a CT scan of the abdomen or pelvis. Ultrasonography in conjunction with Doppler evaluation can provide important information for differential diagnosis and surgical treatment of certain condition. For scrotal lymphangiomas, biopsies confirm the diagnosis, ultrasonography determines the cystic nature and fluid component and guides the surgical strategy [5,4,6].

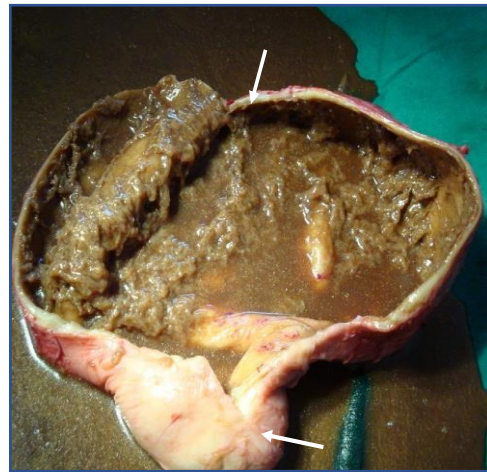


Fig. 9. Photographs showing cyst containing brownish, muddy material with thick wall along with right testis

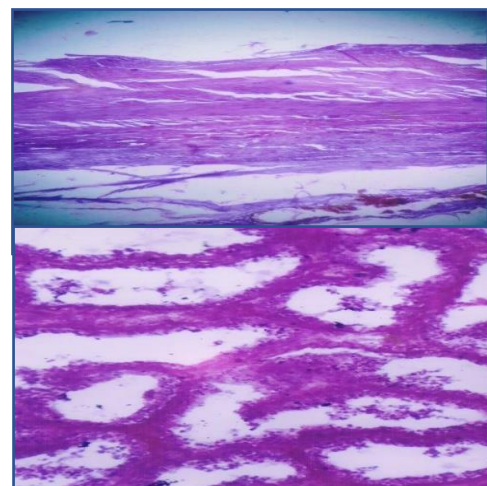


Fig. 10. Histopathological examination revealed multiple dilated spaces lined by a single layer of epithelium filled with lymph

Scrotum is a very uncommon location for cystic lymphangioma, and it should be considered in the differential diagnosis of multiloculated,

benign-appearing extratesticular masses with insufficient vascular supply in an adult. Lymphomography is not advised because cystic lymphangiomas do not communicate with the lymphatic system. Surgical excision of the entire mass is used to treat the disease. Other treatment techniques, such as sclerosant injections, extensive fulguration, and cryotherapy, have failed miserably. Because of the lack of availability in our hospital of other treatment techniques, such as sclerotherapy, we were chosen for surgical excision of the entire mass. The cyst lymphangioma must be removed completely to prevent a recurrence. Complete surgical excision is considered the gold standard treatment modality, and in some cases, orchidectomy may be necessary in adults with extensive cystic lymphangiomas at the epididymis and complete orchidectomy may be required [2,5,4].

3.1 Literature Review

The scrotum and inguinal canal are unusual sites for the development of lymphangiomas, and epididymal lymphangiomas are particularly rare. To the best of our knowledge, only six cases have been reported to date, with the initial case documented by Thompson in 1936. Among the previously reported cases, one resulted from secondary lymphangiomas post-herniorrhaphy, while the remaining five were true primary lymphangiomas [4,6,7].

In 1976, Whimster characterized lymphangiomas as congenital abnormalities stemming from the abnormal development of lymphatic channels. These channels originate from sequestered lymphatic tissue, lacking normal communication with the lymphatic system and presenting as a cystic mass. Singh et al reported 32 cases of cystic lymphangioma in children, with only one located in the scrotum. Loberant et al reported fewer than 50 cases of scrotal cystic lymphangioma until 2002, and Hurwitz et al documented seven cases over a 10-year period [5,4,8].

In our reported case, the patient presented at 35 years of age with two children's and a massive benign cystic lymphangioma extending from the inguinoscrotal region up to the umbilicus. We performed a complete orchidectomy along with the removal of the cystic mass. This case represents the first documentation of such a sizable benign cystic lymphangioma of the epididymis, weighing 3 kg, in the literature [9,10].

4. CONCLUSION

Primary benign cystic lymphangioma of the epididymis is an extremely rare condition. In children's the scrotal cystic lymphangioma is completely excised while preserving the testis and to prevent recurrence. It is the gold standard treatment. So preoperative a proper diagnosis of the scrotal lymphangioma and its extent using the ultrasonography, CT and MRI is essential to planning an appropriate surgical approach.

CONSENT

As per international standards or university standards, patient(s) written consent has been collected and preserved by the author(s).

ETHICAL APPROVAL

As per international standards or university standards written ethical approval has been collected and preserved by the author(s).

COMPETING INTERESTS

Authors have declared that no competing interests exist.

REFERENCES

1. Haroon M, Nisha Y, Iqbal K. Epididymal cystic lymphangioma presenting as scrotal swelling in a post surgery case of carcinoma rectum- A case report. *J Clin Diagn Res.* 2017;11(9):TD03-TD04. doi:10.7860/JCDR/2017/29787.10647 Epub 2017 Sep 1. PMID: 29207807; PMCID: PMC5713829
2. Kok KY, Telesinghe PU. Lymphangioma of the epididymis. *Singapore Med J.* 2002; 43(5):249-50. PMID: 12188077.
3. Abdullahi Yusuf Ali, Abdishakur Mohamed Abdi, Dilek Basar, Shukri Said Mohamed, İsmail Gedi İbrahim, Rare case cystic scrotal lymphangioma presented as a hydrocele, *International Journal of Surgery Case Reports.* Available: <https://doi.org/10.1016/j.ijscr.2022.106959>
4. Yasir S. Jamal FRCS(I), FICS, Abdel-Rahman RE. Abdel-Halim, Sabah S. Moshref1 FRSC(I), Mazen O. Kurdi FRCS(I), and Husain I. Sandugji, CAB Cystic lymphangioma of spermatic cord: A Case report and literature review, *JKAU: Med. Sci.* 2009;16(4):103-111.

- DOI: 10.4197/Med. 16-4.8
5. Stanislav T. Merka, Kaje S. Bhatt, Frederick W. Wood. Cystic lymphangioma of the scrotum: A case report. The Journal of Urology. Available: [https://doi.org/10.1016/S0022-5347\(17\)50863-0](https://doi.org/10.1016/S0022-5347(17)50863-0)
 6. Shivraj Mohan Patil, Moses AW Ingty. An Atypical case of scrotal swelling - masquerading as third testis. International Journal of Health Sciences and Research. 2020;10(3). Available: www.ijhsr.org
 7. Kajal P, Nain Rattan K, S Malik V, Garsa V. Scrotal lymphangioma - A rare cause of scrotal swelling. APSP J Case Rep. 2013; 4(1):5. Epub 2013 Jan 1. PMID: 23277887; PMCID: PMC3525287.
 8. Koubbach Y, Rabii R, El Houry Y, Oqbani K, Bouknani N. Rare case of inguinal cystic lymphangioma diagnosed and treated in elderly patient. SAGE Open Medical Case Reports. 2023;11. DOI: 10.1177/2050313X231185477
 9. Patoulas, Prodromou, Feidantsis, Kallergis, Koutsoumis, Cystic lymphangioma of the inguinal and scrotal regions in childhood - Report of three cases, HIPPOKRATIA. 2014;18(1):88-91.
 10. Thayer Mohammed Ameen Aboush, Zaidoon Moayad Altaee, Mahmood Mosa Mahmood, Cystic lymphangioma: A rare finding during hydrocele surgery in children "case report, Pediatric Urology Case Reports, Pediatr Urol Case Rep. 2020;7(6):155-158 DOI: 10.14534/j-pucr.2020664403

© 2023 Jatal et al.; This is an Open Access article distributed under the terms of the Creative Commons Attribution License (<http://creativecommons.org/licenses/by/4.0>), which permits unrestricted use, distribution, and reproduction in any medium, provided the original work is properly cited.

Peer-review history:

The peer review history for this paper can be accessed here:

<https://www.sdiarticle5.com/review-history/110612>