



Clinical Profile of Ventricular Septal Defect in Children in a Tertiary Care Hospital in Bangladesh

**Md. Abu Sayed Munsi ^{a++*}, Rizwanul Ahsan Bipul ^{b#},
Maher Akther ^{c#} and Md. Abu Sayeed ^{bt}**

^a Department of Paediatric Cardiology, Bangladesh Shishu Hospital and Institute, Dhaka, Bangladesh.

^b Department of Paediatrics, Bangladesh Shishu Hospital and Institute, Dhaka, Bangladesh.

^c Department of Paediatrics, Comilla Medical College and Hospital, Comilla, Bangladesh.

Authors' contributions

This work was carried out in collaboration among all authors. All authors read and approved the final manuscript.

Article Information

Open Peer Review History:

This journal follows the Advanced Open Peer Review policy. Identity of the Reviewers, Editor(s) and additional Reviewers, peer review comments, different versions of the manuscript, comments of the editors, etc are available here: <https://www.sdiarticle5.com/review-history/106730>

Original Research Article

Received: 03/08/2023

Accepted: 09/10/2023

Published: 14/10/2023

ABSTRACT

Background: Ventricular septal defect (VSD) is the most prevalent congenital heart abnormality, comprising a quarter of all cases. When these VSDs are small and cause a left-to-right shunt, patients often remain asymptomatic, with the condition typically detected during routine physical examinations. On the other hand, larger VSDs can lead to a range of distressing symptoms in infants, including difficulty breathing, feeding challenges, inadequate growth, excessive sweating, and even early-onset cardiac failure.

Objective: The objective of the study was to analysis the clinical profile and size and type of VSD in Paediatric patients admitted in a tertiary care hospital in Dhaka, Bangladesh.

Methods: This prospective cross-sectional study spanned six months, commencing in January 2022 and concluding in June 2022. The research was conducted within the Department of Pediatric

⁺⁺Associate Professor;

[#]Assistant Professor;

[†]Associate Professor & Head;

^{*}Corresponding author: Email: sayedmn11@gmail.com;

Cardiology at the Bangladesh Shishu Hospital and Institute. The study focused on children aged one month to eighteen who had received a clinical diagnosis of Ventricular Septal Defect (VSD). The confirmation of this diagnosis was achieved through echocardiography. Only cases where VSD was the sole cardiac abnormality were included in the study cohort. Data collection and subsequent analysis were conducted using SPSS version 24.0.

Results: Among the total of 135 cases, 55.6% were male and 44.4% were female with male female ratio 1.25:1. 76.3 % cases presented in 1st year of life. Perimembranous VSD was the commonest (79.3%) followed by muscular (8/1%), Inlet (7.4%) and doubly committed VSD (5.2%). Common symptoms were cough (98.5%), fever (88.1%), breathlessness (85.1%), feeding problem (83.7%), failure to thrive (74.8%) and common sign were Pansystolic murmur (100%), tachypnea (98.5%), tachycardia (70/4%), crepitation (91.1%), subcostal retraction (98.5%), hepatomegaly (70.4%) and wheeze (7.4%) were the frequent clinical findings. Down syndrome associated with inlet VSD (2.9%). Complications associated with VSD were pneumonia (91.1%), malnutrition (74.8%), congestive cardiac failure (CCF) (70.4%), Eisenmenger syndrome (1.5%) and Infective endocarditis (1.5%).

Conclusion: The perimembranous type is the most prevalent form of Ventricular Septal Defect (VSD). VSDs that are moderate to large can lead to severe symptoms and various complications. Timely identification and appropriate treatment are crucial in averting these associated complications, ultimately decreasing mortality and morbidity rates among affected children.

Keywords: Ventricular septal defect; pansystolic murmur; echocardiography; infective endocarditis.

1. INTRODUCTION

Ventricular Septal Defect (VSD) stands as the most prevalent congenital cardiac anomaly, constituting 25% of all cases of congenital heart disease (CHD) [1]. The discovery of VSD dates back to 1847, when Dalrymple first identified this condition [2]. Isolated VSD occurs in approximately 2-6 out of every 1000 live births [3,4]. VSD is characterized by a developmental flaw in the interventricular septum, stemming from insufficient growth, misalignment, or the failure of parts to fuse properly within the ventricular septum [5]. This septum consists of four distinct components: the membranous, muscular (often called trabecular), infundibular, and atrioventricular or inlet portions [6,7]. VSDs are categorized into four types based on their location: perimembranous, muscular or trabecular, infundibular/outlet/supracristal/doubly committed, and atrioventricular/inlet VSD. Additionally, they can be classified by size relative to the diameter of the aortic annulus. Sizes include small ($\leq 25\%$ of aortic annulus diameter), medium ($>25\%$ but $<75\%$ of aortic annulus diameter), and large ($>75\%$ of aortic annulus diameter) [6,7]. Perimembranous defects are the most prevalent, accounting for approximately 70-80% of cases [8,9]. The progression of a Ventricular Septal Defect (VSD) differs depending on the size of the defect. Small VSDs, characterized by minor left-to-right shunting and normal pulmonary artery pressure, usually do not cause symptoms and are

frequently detected during routine physical check-ups. On the other hand, larger VSDs, which result in increased blood flow to the lungs and elevated pulmonary pressure, can manifest with early infant symptoms such as difficulty breathing, trouble with feeding, inadequate growth, excessive sweating, and heart failure [1]. Prolonged large left-to-right shunts can cause irreversible changes in the pulmonary vascular endothelium, resulting in persistent pulmonary arterial hypertension (PAH). When the pulmonary circulation pressure exceeds that of the systemic circulation, the shunt direction reverses, leading to what is known as Eisenmenger syndrome, which affects 10% to 15% of VSD patients. In diagnostic techniques, Color Doppler transthoracic echocardiography (TTE) takes center stage as an invaluable tool, primarily due to its remarkable sensitivity. When detecting ventricular septal defects (VSDs), Color Doppler TTE demonstrates exceptional performance, identifying as many as 95% of these defects, particularly those non-apical lesions that exceed 5 mm in size. This diagnostic modality delivers comprehensive insights into the morphology of VSDs, including their dimensions, locations, and the number of defects. It also provides crucial hemodynamic information such as the jet's size, the defect's severity, and an estimation of pulmonary artery pressure [10,11]. Electrocardiography (ECG) appears normal in half of VSD patients, but it may reveal left ventricular hypertrophy in those with large shunts. Patients with PAH may exhibit ECG

abnormalities like right bundle branch block, right axis deviation, right ventricular hypertrophy and strain. Chest radiography (CXR) may not always reveal noticeable abnormalities in individuals with small defects. However, an enlarged cardiac silhouette may become apparent in cases of larger defects and an enlarged left ventricular size. Pulmonary arterial hypertension (PAH) can manifest as an enlarged right ventricle and an increased pulmonary diameter, which can be detected on CXR images. Cardiac catheterization provides precise hemodynamic data on pulmonary vascular resistance and the response to vasodilators, making it particularly valuable for assessing patients being considered for surgical closure [9]. Our study endeavours to present a comprehensive overview of VSD cases in children within the pediatric cardiology department of Bangladesh Shishu Hospital and Institute. This tertiary care centre, in Dhaka, Bangladesh, serves as a referral hub for patients nationwide. The outcomes of this study aim to enhance early diagnosis and proper management, ultimately leading to reduced mortality and morbidity rates.

2. MATERIALS AND METHODS

The research was carried out at the Department of Pediatric Cardiology within Bangladesh Shishu Hospital and Institute in Dhaka. The study was conducted from January 2022 to June 2022. During this period, all children aged between 1 month and 18 years admitted with a clinical diagnosis of Ventricular Septal Defect (VSD) underwent echocardiography to confirm the diagnosis. The study exclusively included cases of isolated VSD, meaning no other cardiac anomalies were present. The size and location of the VSDs were determined using two-dimensional transthoracic colour Doppler

echocardiography. Patients were categorized into three distinct classes based on the aortic annulus size. Specifically, they were classified as small if the VSD measured equal to or less than 25% of the aortic annulus diameter, medium if it measured more than 25% but less than 75%, and large if the VSD exceeded 75% of the aortic annulus diameter. Furthermore, VSDs were classified based on location, including perimembranous VSD, muscular or trabecular VSD, infundibular or outlet or supracristal or doubly committed VSD, and atrioventricular or inlet VSD. In addition to echocardiography, a comprehensive assessment of each case involved:

- Taking a detailed medical history.
- Conducting anthropometric measurements.
- Performing chest X-rays.
- Obtaining electrocardiograms (ECGs).

Anthropometric measurements were carried out by the standardized procedures outlined by the World Health Organization (WHO). The collected data was subsequently entered into a database and analyzed using SPSS version 24.0.

3. RESULTS

Table 1. Gender distribution of the patients (N=135)

Out of the total patients, 75(55.6%) were Male and 60(44.4%) were female. Male: female ratio was 1.25:1.

Gender	Frequency (n)	Percentage (%)
Male	75	55.6%
Female	60	44.4%

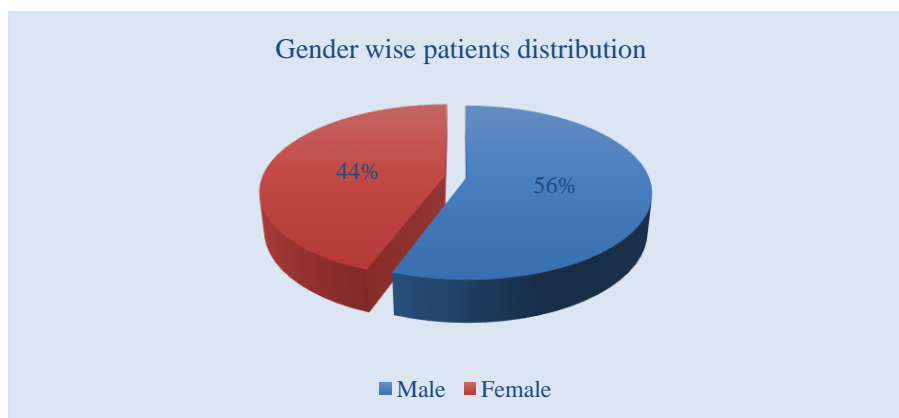


Fig. 1. Pie chart showed the gender distribution of the patients. (N=135)

Table 2. Age group wise patient’s distribution (N=135)

Among the 135 patients, 103(76.3%) patients were below one year of age at presentation and only 3(2.2%) patient had present after 5 years of age.

Patients Age Group	Frequency (n)	Percentage (%)
1 month to 1 year	103	76.3%
>1 year to 5 years	29	21.5%
>5 years to 18 years	3	2.2%

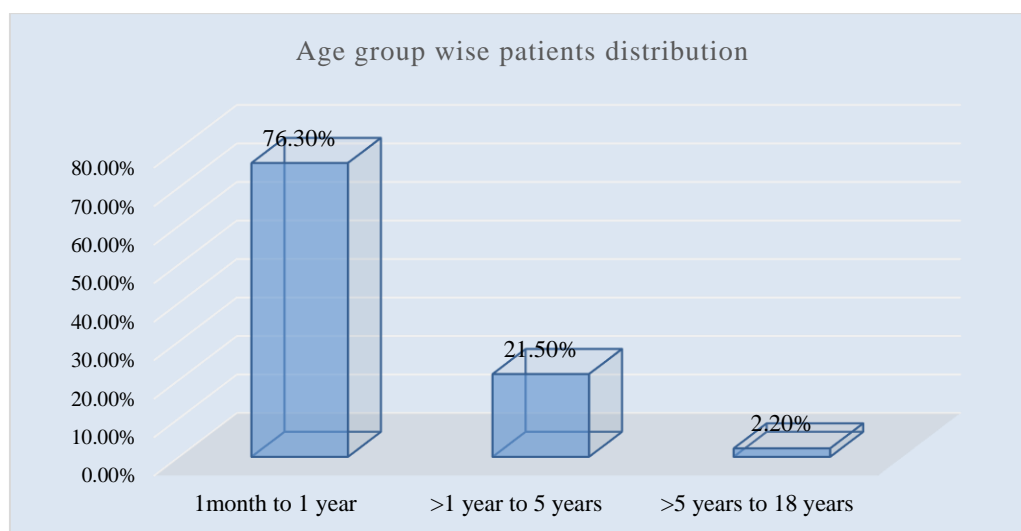


Fig. 2. Colum chart showed age group wise patients (N=135)

Table 3. Symptoms of admitted VSD patients (N=135)

Regarding the clinical presentation, 133(98.5%) of patients presented with cough and 118(88.1%) patient presented with fever. Other presentation includes breathlessness 115(85.1%), feeding problem 113(83.7%), failure to thrive 101(74.8%).

Symptoms	Frequency (n)	Percentage (%)
Cough	133	98.5%
Fever	118	88.1%
Breathlessness	115	85.1%
Feeding problem	113	83.7%
Failure to thrive	101	74.8%

Table 4. Sign of admitted VSD patients (N=135)

The major signs in order of frequency were pansystolic murmur 135(100%), tachypnea 133(98.5%), subcostal retraction 133(98.5%), crepitation 123(91.1%), tachycardia 95(70.4%), hepatomegaly 95(70.4%), Cardiomegaly 95(70.4%) and wheeze 10(7.4%).

Signs	Frequency (n)	Percentage (%)
Tachycardia	95	70.4%
Tachypnea	133	98.5%
Subcostal retraction	133	98.5%

Signs	Frequency (n)	Percentage (%)
Crepitation	123	91.1%
Wheeze	10	7.4%
Hepatomegaly	95	70.4%
Cardiomegaly	95	70.4%
Pansystolic murmur	135	100%

Table 5. Syndrome associated with VSD patients (N=135)

Among 135 patients, 4(2.9%) was diagnose as a case of down syndrome (2.9%) on the basis of clinical findings and 1(0.7%) patient was Turner syndrome.

Syndrome associated with VSD	Frequency (n)	Percentage (%)
Down syndrome	4	2.9%
Turner syndrome	1	0.7%

Table 6. Types of VSD according to anatomical location (N=135)

Among the VSD cases, 107(79.3%) children had perimembranous VSD, 11(8.1%) had muscular VSD and 10(7.4%) patient had inlet VSD and 7(5.2 %) had outlet type of VSD.

Anatomical type of VSD	Frequency (n)	Percentage (%)
Perimembranous VSD	107	79.3%
Muscular / Trabecular VSD	11	8.1%
Atrioventricular / Inlet VSD	10	7.4%
Outlet / supracristal / doubly committed VSD	7	5.2%

Table 7. Types of VSD on basis of size of aortic annulus (N=135)

Echocardiography done in the study subjects found 5(3.7 %) cases had small VSD, 39(28.9%) cases had moderate VSD, while 91(67.4%) cases had large VSD.

Type of VSD on basis of size	Frequency (n)	Percentage (%)
Small VSD	5	3.7%
Moderate VSD	39	28.9%
Large VSD	91	67.4%

Table 8. Complications of patient with VSD (N=135)

Among the complications that were frequently associated were pneumonia 123(91.1%) followed by Malnutrition 101(74.8%) and CCF 95(70.4%). 2(1.5%) patients present with infective endocarditis and 2(1.5%) patients present with Eisenmenger syndrome. Among the 101 cases of malnutrition, 63(46.7%) patients had severe malnutrition and 38(28.1%) patients had moderate malnutrition. Complications were mostly observed in moderate-to-large VSD.

Complications	Small VSD (n=5)	Moderate VSD (n=39)	Large VSD (n=91)	Total (N=135)
Pneumonia	2 (40%)	30 (76.9%)	91 (100%)	123(91.1%)
Bronchiolitis	3(60%)	7(17.9%)	Nil	10(7.4%)
CCF	Nil	15(38.5%)	80(87.9%)	95(70.4%)
Infective endocarditis	Nil	2(5.1%)	Nil	2(1.5%)
Malnutrition	Nil	20(51.3%)	81(89.01%)	101(74.8%)
Eisenmenger syndrome	Nil	Nil	2(2.2%)	2(1.5%)

Table 9. Feeding history of patient with ventricular septal defect (N-135)

Regarding feeding history, only 45(33.3%) patients on exclusive breast feeding, 66(48.9%) patient on breast feeding + formula feeding and 24(17.8%) patient on formula feeding only.

Breast feeding history	Frequency (n)	Percentage (%)
Exclusive breast feeding	45	33.3%
Breast feeding + formula	66	48.9%
Only Formula feeding	24	17.8%

Among the other investigations, chest X-ray finding of cardiomegaly and plethora were seen in 95(70.3%) cases, ECG was normal in 41(30.4%) cases, 68(50.4%) cases had left ventricular hypertrophy, 17(12.6%) cases had right ventricular hypertrophy and 9(6.6%) cases had biventricular hypertrophy

4. DISCUSSION

Ventricular septal defect (VSD) is children's most common cyanotic congenital heart condition. A comprehensive understanding of the clinical characteristics of VSD is crucial for early diagnosis and effective treatment, ultimately reducing the risk of complications. Our study focuses on patients admitted to the Department of Pediatric Cardiology at Bangladesh Shishu Hospital and Institute, Bangladesh's largest tertiary care children's hospital, serving patients nationwide. Our study observed a higher prevalence of VSD in males, with a male-to-female ratio of 1.25:1, consistent with findings reported by Kazmi et al. [12] and Chaudhry et al. [13]. Most cases (76.3%) presented during infancy, which aligns with the research conducted by Hussain et al. [14]. Regarding the size of VSD, we observed that 3.7% were small, 28.9% were moderate, and 67.4% were large, with a similar pattern reported by Ramachandran et al. [15]. The perimembranous type was the most common anatomical subtype (79.3%), followed by the muscular type (8.1%), inlet type (7.4%), and the least frequent outlet type (5.2%), consistent with studies conducted in Western countries [16]. Regarding clinical presentation, the most common symptoms included cough, fever, breathlessness, feeding difficulties, and failure to thrive, corroborating other studies' findings [17]. Clinical signs such as pan systolic murmur, tachypnea, tachycardia, crepitations, subcostal retraction, hepatomegaly, cardiomegaly, and wheezing were frequently observed, consistent with findings in other developing countries [18,17]. Complications were notable in our study, with congestive heart failure

(CCF) present in 70.4% of patients, particularly in cases with moderate-to-large VSD. This contrasts with the study by Sharmin et al., where only 30% of patients presented with CCF [17]. Additionally, we found that the size of VSD affected growth, with a higher prevalence of malnutrition in cases with large VSD (89.01%) and moderate VSD (51.3%). Severe malnutrition was present in 46.7% of cases and moderate malnutrition in 28.1%, a pattern similar to that observed by Quasy et al. [19]. Two patients were diagnosed with Infectious endocarditis, and two developed Eisenmenger syndrome. Regarding feeding practices, 33.3% of patients were exclusively breastfed, 48.9% received a combination of breast and formula feeding, and 17.8% were exclusively formula-fed. This variation may be attributed to difficulties in breastfeeding and failure to thrive, particularly in cases with large VSD, prompting parents to opt for formula feeding. Chest X-ray findings revealed cardiomegaly and plethora in 70.3% of cases, consistent with findings by Harshangi et al. [18]. ECG results showed that 30.4% of cases had a normal ECG, 50.4% had left ventricular hypertrophy, 12.6% had right ventricular hypertrophy, and 6.6% had biventricular hypertrophy. These ECG findings were comparable to those reported by Hussain et al. [14], with normal ECG in 28% of cases and left axis deviation (65.3%) as the most significant ECG abnormality. While the rate of exclusive breastfeeding in Bangladesh stands at 65%, our study found lower rates, likely due to the challenges faced by patients with large VSD in breastfeeding and their subsequent failure to thrive, leading parents to opt for formula feeding.

5. CONCLUSION

The perimembranous type was the most prevalent form of ventricular septal defect (VSD). Infancy was the primary period when patients with VSD typically sought medical attention. Notably, moderate and large VSDs often manifested with severe symptoms. Patients with

moderate-to-large VSDs frequently experience complications such as pneumonia, congestive heart failure (CHF), malnutrition, and failure to thrive. The timely identification and treatment of VSDs can be crucial in preventing these associated complications, ultimately reducing the mortality and morbidity rates in affected children.

CONSENT

It is not applicable.

ETHICAL APPROVAL

It is not applicable.

COMPETING INTERESTS

Authors have declared that no competing interests exist.

REFERENCES

1. Bernstein D. Acyanotic congenital heart disease: The left-to-right shunt lesions. In: Behrman RE, Kliegman RM, Jenson HB, et al. (eds). Nelson Textbook of Paediatrics. 17th ed. W.B. Saunders Co, 2004:1888-90.
2. Ammash NM, Warnes CA. Ventricular septal defects in adults. *Ann Intern Med.* 2001 Nov 06;135(9):812-24. [PubMed]
3. Samanek M, Voriskova M. Congenital heart disease among 815, 569 children born between 1980 and 1990 and their 15-year survival: a prospective bohemian survival study. *Paediatr Cardiol* 1999;20(6):411-7.
4. Tynan M, Anderson RH. Ventricular septal defect. In: Anderson RH, Baker EJ, McCartney FJ, (eds.) *Paediatric Cardiology*. London: Churchill Livingstone, 2002:983-1014.
5. Praagh R, Geva T, Kreutzer J. Ventricular septal defects: how shall we describe, name and classify them? *J Am Coll Cardiol* 1989;14(5):1298-9.
6. Patel ND, Kim RW, Pornrattananarungsri S, Wong PC. Morphology of intramural ventricular septal defects: Clinical imaging and autopsy correlation. *Ann Pediatr Cardiol.* 2018 Sep-Dec;11(3):308-311. [PMC free article] [PubMed]
7. Lopez L, Houyel L, Colan SD, Anderson RH, Béland MJ, Aiello VD, et al. Classification of Ventricular Septal Defects for the Eleventh Iteration of the International Classification of Diseases-Striving for Consensus: A Report from the International Society for Nomenclature of Paediatric and Congenital Heart Disease. *Ann Thorac Surg.* 2018 Nov;106(5):1578-1589. [PubMed]
8. Wickramasinghe P, Lamabadusuriya SP, Nerenthiran S. Prospective study of congenital heart disease in children. *Ceylon Med J* 2001;46(3):96-8.
9. Perloff JK. *Clinical recognition of congenital heart disease*. Philadelphia, PA. Saunders; 2003.
10. Maagaard M, Heiberg J, Eckerström F, Asschenfeldt B, Rex CE, Ringgaard S, Hjortdal VE. Biventricular morphology in adults born with a ventricular septal defect. *Cardiol Young.* 2018 Dec;28(12):1379-1385. [PubMed]
11. Hadeed K, Hascoët S, Karsenty C, Ratsimandresy M, Dulac Y, Chausseray G, Alacoque X, Fraise A, Acar P. Usefulness of echocardiographic-fluoroscopic fusion imaging in children with congenital heart disease. *Arch Cardiovasc Dis.* 2018 Jun-Jul;111(6-7):399-410. [PubMed]
12. Kazmi U, Sadiq M, Hyder SN. Pattern of ventricular septal defects and associated complications. *J Coll Physicians Surg Pak* 2009;19(6):342-5.
13. Chaudhry TA, Younas M, Baig A. Ventricular septal defect and associated complications. *J Pak Med Assoc* 2011; 61(10):1001-4.
14. Hussain M, Hussain S, Krishin J, et al. Presentation of congestive cardiac failure in children with ventricular septal defect. *J Ayub Med Coll Abbottabad* 2010;22(4): 135-8.
15. Ramachandran U, Alurkar V, Thaplia A. Pattern of cardiac diseases in children in Pokhara, Nepal. *Kathmandu Univ Med J* 2006;4(2):222-7.
16. McDaniel NL, Gutgesell HP. Ventricular septal defect. In: Allen HD, Driscoll DJ, Shetty RE, et al. (eds.) *Moss and Adams' Heart Disease in Infants, Children and Adolescent*. 7th ed. Philadelphia: Lippincott Williams & Wilkins, 2008:667-82.
17. Sharmin L, Haque M, Bari M, et al. Pattern and clinical profile of congenital heart disease in a teaching hospital. *TAJ: J of Teachers Assoc* 2008;21(1):58-62.

18. Harshanghi S, Itagi L, Patil V, et al. Clinical study of congenital heart disease in infants in tertiary care hospital. Journal of Pharmaceutical and Scientific Innovation 2013;2(1):15-8.
19. Qusay A, Al-Rahim, Al-Hamash S, et al. Effect of ventricular septal defect on the growth pattern of children. The Iraqi Postgraduate Medical Journal 2006;5(1): 8-13.

© 2023 Munsi et al.; This is an Open Access article distributed under the terms of the Creative Commons Attribution License (<http://creativecommons.org/licenses/by/4.0>), which permits unrestricted use, distribution, and reproduction in any medium, provided the original work is properly cited.

Peer-review history:

The peer review history for this paper can be accessed here:

<https://www.sdiarticle5.com/review-history/106730>