

## The venous drainage of the corpora cavernosa in the human penis

Geng-Long Hsu, Yi-Ping Hung, Mang-Hung Tsai, Hong-Chiang Chang, Shi-Ping Liu, Eugen Molodysky & Michael Chih-Yuan Hsu

To cite this article: Geng-Long Hsu, Yi-Ping Hung, Mang-Hung Tsai, Hong-Chiang Chang, Shi-Ping Liu, Eugen Molodysky & Michael Chih-Yuan Hsu (2013) The venous drainage of the corpora cavernosa in the human penis, Arab Journal of Urology, 11:4, 384-391, DOI: [10.1016/j.aju.2013.04.002](https://doi.org/10.1016/j.aju.2013.04.002)

To link to this article: <https://doi.org/10.1016/j.aju.2013.04.002>



© 2013 Arab Association of Urology



Published online: 05 Apr 2019.




Submit your article to this journal [↗](#)



Article views: 774



View related articles [↗](#)



ANDUROLOGY / SEXUAL MEDICINE

ORIGINAL ARTICLE

# The venous drainage of the corpora cavernosa in the human penis



Geng-Long Hsu <sup>a,d,\*</sup>, Yi-Ping Hung <sup>b</sup>, Mang-Hung Tsai <sup>c</sup>, Hong-Chiang Chang <sup>d</sup>, Shi-Ping Liu <sup>d</sup>, Eugen Molodysky <sup>e</sup>, Michael Chih-Yuan Hsu <sup>a</sup>

<sup>a</sup> *Microsurgical Potency Reconstruction and Research Center, Taipei, Taiwan*

<sup>b</sup> *Department of Physiology, China Medical University, Taichung, Taiwan*

<sup>c</sup> *Department of Anatomy, China Medical University, Taichung, Taiwan*

<sup>d</sup> *Department of Urology, National Taiwan University Hospital, College of Medicine, Taipei, Taiwan*

<sup>e</sup> *Discipline of General Practice, Sydney School of Medicine, University of Sydney, Australia*

Received 15 March 2013, Received in revised form 5 April 2013, Accepted 7 April 2013

Available online 16 May 2013

## KEYWORDS

Cavernous vein;  
Drainage;  
Corpora cavernosa;  
Venous;  
Cadaver

## ABBREVIATIONS

DDV, deep dorsal vein;  
CVs, cavernous veins;  
PAVs, para-arterial

**Abstract Objective:** To study the drainage proportions from the corpora cavernosa in defrosted human cadavers, as the veins related to penile erection were recently depicted to comprise the deep dorsal vein (DDV), a pair of cavernous veins (CVs) and two pairs of para-arterial veins (PAVs), as opposed to a single DDV between Buck's fascia and the tunica albuginea of the human penis.

**Materials and methods:** With no formalin fixation, 10 defrosted male human cadavers were used for this study. After injecting a 10% solution of colloid, and with the intracavernous pressure (ICP) fixed at 90 mmHg, the perfusion rate was recorded before and after the DDV, CVs and PAVs were removed, respectively. Finally, measurements were again recorded after penile arterial ligation. Cavernosography was used if required.

**Results:** The mean (range) perfusion rate for maintaining the ICP at 90 mmHg was 30.2 (15.5–90.8) mL/min, whereas the arterial perfusion rate was 2.8 (0.3–

\* Corresponding author. Address: Microsurgical Potency Reconstruction and Research Center, 3F 88, Wen-Hu Street, Nei-Hu Dt. 114, Taipei, Taiwan. Tel.: +886 2 87526087; fax: +886 2 87975207.

E-mail addresses: [genglonghsu@gmail.com](mailto:genglonghsu@gmail.com), [glhsu@ha.mc.ntu.edu.tw](mailto:glhsu@ha.mc.ntu.edu.tw) (G.-L. Hsu).

Peer review under responsibility of Arab Association of Urology.



Production and hosting by Elsevier

veins;  
ICP, intracavernous  
pressure;  
ED, erectile  
dysfunction

3.9) mL/min. The mean (range) drainage proportion of the corpora cavernosa was 60.5 (50.3–69.7)%, 11.9 (5.8–22.9)% and 11.4 (5.2–15.0)% via the DDV, CVs and PAVs, respectively. The remaining drainage proportion was 15.6 (14.1–18.1)%. This study shows the separate drainage contributions of the DDV, CVs and PAVs to the corpora cavernosa of the human penis.

**Conclusion:** We conclude that the venous drainage system of the corpora cavernosa is much more complex than the previous depictions of it, and the consequent focus on a single DDV. This also shows the independent role of each venous system.

© 2013 Production and hosting by Elsevier B.V. on behalf of Arab Association of Urology.

## Introduction

The venous system of the human penis has been widely studied, and it is generally accepted that a single deep dorsal vein (DDV), accompanied by a pair of dorsal arteries positioned between the Buck's fascia and the tunica albuginea, facilitates venous drainage [1,2]. However, a recent study [3] showed a more complex venous anatomy in which a DDV, a pair of cavernous veins (CVs) and two pairs of para-arterial veins (PAVs) are shown between Buck's fascia and the tunica albuginea. The DDV, consistently located in a median position, receives the blood of the emissary veins from the corpora cavernosa and of the circumflex vein from the corpus spongiosum. It is sandwiched by a pair of CVs, although these lie in a deeper position. Bilaterally, each dorsal artery is sandwiched by its corresponding medial and lateral PAVs, respectively. These veins are independently responsible for draining the sinusoidal blood of the corpora cavernosa into the systemic circulation.

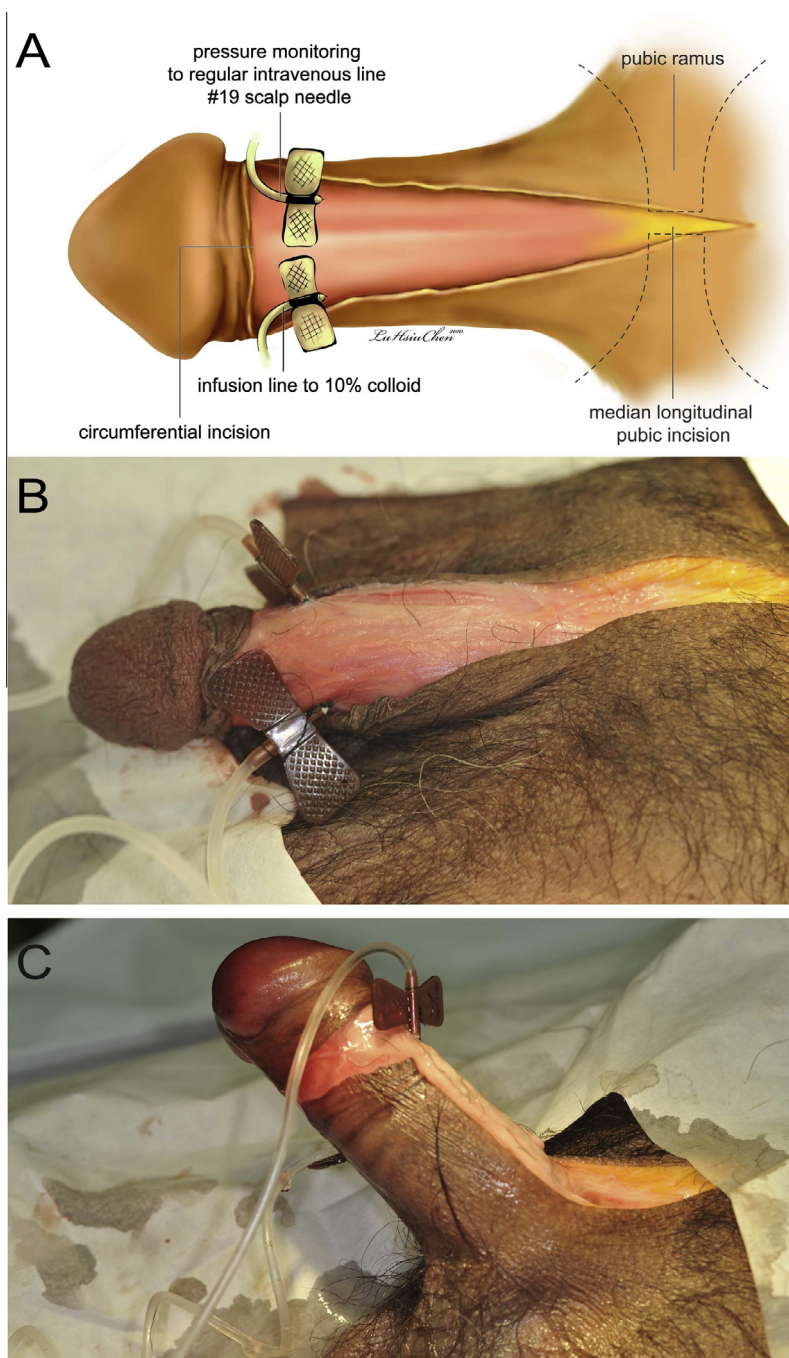
The concept of DDV varicosity was first introduced in the 19th century [4], and the first surgery on the DDV to treat atonic impotence reported in 1902 [5]. Similar attempts were not reported on a larger scale for a further five decades [6], and the surgery did not achieve popularity until 1985 [7]. Penile venous surgery was unfortunately almost abandoned because the general consensus on it as a treatment for erectile dysfunction (ED) was that it only resulted in temporary success, i.e. of 1–2 years. Accordingly, in 1996 and after a meta-analysis of the literature, the clinical guidelines panel of the AUA supported this view and declared that venous surgery was not justified for routine use in treating ED [8]. In hindsight, the eventual recurrence of ED in men treated by venous surgery seemed unavoidable given that knowledge of the venous anatomy remained limited to the traditional understanding [9,10], and given that electrocauterisation was so often used [11,12]. It seems that more accurate knowledge of tunical and venous anatomy is crucial in achieving a favourable surgical outcome [13]. This new insight inspired us to further explore the respective contribution of venous drainage in the corpora cavernosa.

## Materials and methods

The study was approved by the institutional review board of China Medical University, conducted from November 2009 to May 2012, and included 10 male defrosted human cadavers, obtained in the previous 3 months, that were frozen with no formalin fixation and within 10 h of death, and in which the penises were intact. To facilitate venous access, a semi-circumferential incision, followed by a median longitudinal incision (Fig. 1) was made superficial to Colles' fascia, from the retrocoronal sulcus along the penile shaft to the upper margin of the symphysis pubis. Two 19-G scalp needles were inserted and firmly fixed in place, with 5–0 Nylon sutures at the 3 and 9 o'clock positions, respectively.

One needle was connected to an infusion pump (ML172 peristaltic pump and ML 175 STH pump controller, AD Instruments Pty Ltd., Bella Vista, NSW, Australia) and was used to inject a 10% colloid solution (Haes-steril, Fresenius-Klinik, Bad Homburg, Germany) into the corpora cavernosa, whereas the other needle was used to monitor the intracavernous pressure (ICP) via an intravenous set connected to a negative-feedback pressure-monitoring system. The perfusion rate was recorded (Fig. 2) while the ICP was set at 90 mmHg before (overall intact reading) and after the DDV, CVs and PAVs were meticulously removed, in sequential order, until they were absent from the corpora cavernosa. Cavernosography was used when required (Fig. 3).

The new insight into the penile venous anatomy was used as a blueprint for venous removal in this study (Fig. 4A). Initially, the DDV was thoroughly stripped and ligated, closest to the tunica albuginea, with 5–0 Nylon sutures, distal to the level of the retrocoronal sulcus, where the number of veinlets can be several dozen, and laterally as close as possible to the junction between the corpus spongiosum and the corpora cavernosa. Further dissection was performed with the aid of two 8.0 × 1.6-cm right-angled retractors that were sufficiently long to reach the deep-rooted vessels, which were at least 7-cm deep (Fig. 4B), until the infrapubic angle was encountered. Similarly, the CVs were resected and ligated, and then the PAVs were segmentally ligated only (Fig. 4C). Finally, the penile shaft was further

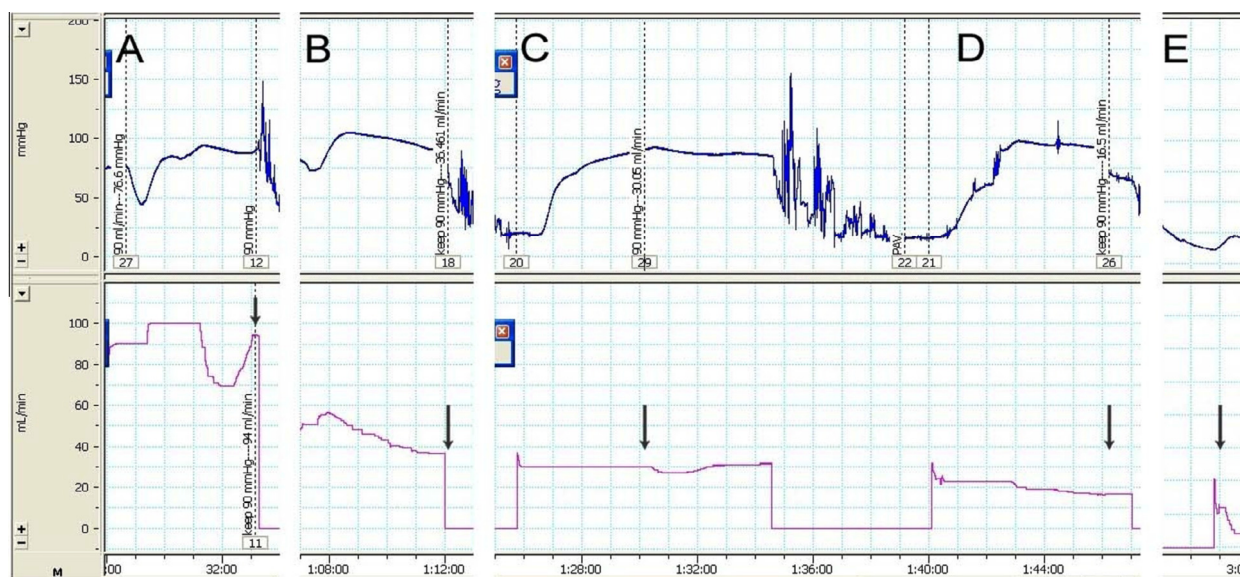


**Figure 1** A schematic illustration and photographs of a representative cadaver in the study. (A) An illustration of the surgical approach and the placing of two scalp needles in the corpora cavernosa. A semi-circumferential incision was made, followed by a dorsal median longitudinal incision extending to the upper margin of symphysis pubis. Two 19-G scalp needles were inserted and firmly fixed in place with 4-0 silk sutures at the 3 and 9 o'clock positions, respectively. One was connected to monitor the ICP, whereas the other was used for infusion of a 10% colloid solution. (B) A representative photograph of a cadaver. This penis was well-prepared with the necessary arrangement depicted in Panel A. It was ready for the overall haemodynamic study with the ICP simultaneously measured. (C) The penis was infused with the 10% colloid solution and the flow rate was recorded, while the ICP oscillated around 90 mmHg. A ventral curvature was characteristic in this cadaver.

released from the pubic angle to expose the penile crura bilaterally, followed by ligation of the penile artery at the branching point of the dorsal artery and cavernous artery proximally. Again, the perfusion rate was

recorded while the ICP was fixed at 90 mmHg. The semi-circumferential incision and the median longitudinal incisions were closed with a running 4-0 chromic suture; the cadavers were then fixed in formalin for routine





**Figure 2** A perfusion rate recording of a representative cadaver (No. 6 in Table 1). (A) An overall haemodynamic study was first made and the perfusion rate was measured as 94.0 mL/min (arrow) while the ICP was oscillating around 90 mmHg. The upper tracing shows the ICP (mmHg), and the lower one represents the infusion flow of 10% colloid solution. (B) This tracing was likewise made after the DDDV and its branches were removed. The perfusion rate was 36.5 mL/min (arrow). (C) Similarly, the perfusion rate of 30.1 mL/min (arrow) was recorded after the CVs were stripped and then ligated. (D) The PAVs were ligated segmentally only. Again a perfusion rate of 16.5 mL/min (arrow) was recorded. (E) Finally, the penile artery was identified and ligated at the branching point of the dorsal and cavernous artery proximally. The perfusion rate was 13.3 mL/min (arrow). It was used for calculating the assumed arterial perfusion rate, and a corrected perfusion rate was made in each setting.

anatomical study by the medical school. Overall, for each cadaver, five readings were recorded for analysis.

### Statistical analysis

In descriptive statistics, the perfusion rates for the overall haemodynamics (and the individual DDDV, CVs and PAVs) were corrected by subtracting the assumed arterial perfusion rate. Their corresponding ratio was calculated by dividing each corresponding number by its corrected perfusion rate of the overall haemodynamics.

## Results

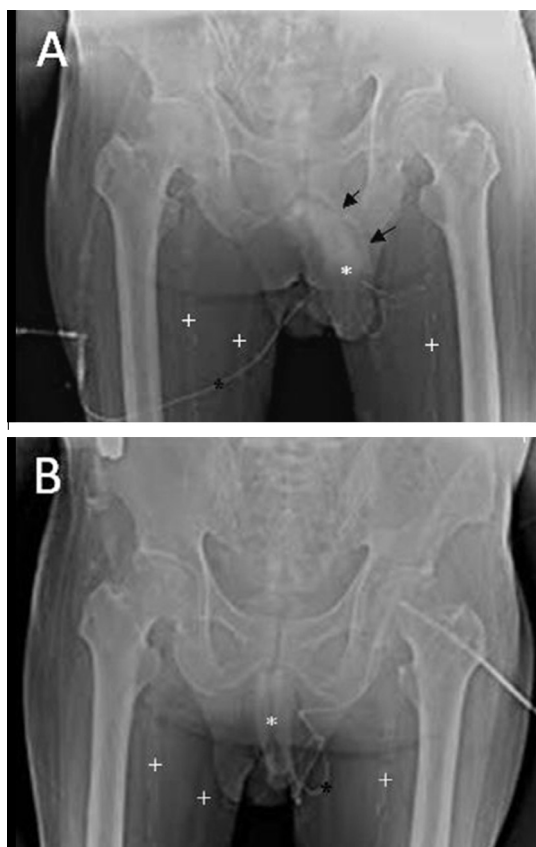Data for one cadaver were excluded because it was used for calibration, and data for another two were excluded due to extreme postmortem changes. Table 1 summarises the demographic data of the seven cadavers included in the study. Overall, the mean (range) drainage proportion of the corpora cavernosa was 60.5 (50.3–69.7)%, 11.9 (5.8–22.9)% and 11.4 (5.2–15.0)% via the DDDV, CVs and PAVs, respectively. The remaining drainage proportion was 15.6 (14.1–18.1)%.

## Discussion

In late 2002 we first attempted a similar haemodynamic study in a clinical setting, in which no prostaglandin was injected. However, it was inconclusive because of

inconsistent data resulting from digital compression on the penile crura, a necessary manoeuvre to reduce the induction volume and to avoid cardiac stress, despite the digital compression being applied perfectly in two of the eight patients. The study was then adapted to the penis of formalin-fixed cadavers, whose loss of tissue extensibility made attaining an ICP of 90 mmHg impossible. We subsequently used defrosted fresh cadavers with no formalin fixation, and this new method solved the two dilemmas: First, it circumvented concerns for cardiac health (and precluded the possibility of psychological variables) that are natural to a clinical setting, and second, it eliminated the tissue alteration that occurs in formalin-fixed cadavers. This new model enabled many direct experiments, although there were admittedly few suitable cadavers available, despite the legality of our studies in Taiwan [14]. Initially, we planned to use serial cavernosography for confirmation, but this was not feasible because the contrast medium could not drain from the cadaveric penis. Also, the time required after death for cadavers in the study (the number of recommended hours to wait after a subject's death) is unknown [15]. These small setbacks notwithstanding, we attempted to extend this model to a further haemodynamic study. In addition, the sample size was restricted because there were few cadavers available within our traditional culture.

An ICP of 90 mmHg was chosen for this study because from our extensive experience in haemodynamic studies, both on clinical patients and human cadavers,



**Figure 3** Cavernosograms taken in the cadaver of a 67-year-old man. (A) While the tip of a 19-G scalp needle (black asterisk) was positioned in the corpus cavernosum (white asterisk) the DDV (black arrows) is shown after injection with the contrast medium. Note that the femoral vein (cross) was full of blood clots in this defrosted cadaver. (B) Those venous tissues on Panel A were difficult to see after the PAVs were removed and the corpora cavernosa (white asterisk) was better opacified.

we know that an ICP of 90 mmHg is the starting point for erection of the penile shaft. This pressure might be optimal for venous drainage from the corpora cavernosa, as an excessively high ICP might impede the venous drainage and an excessively low one might be insufficient to seal off the emissary veins at the transitional zone between the inner and outer longitudinal layer of the tunica albuginea [16]. We chose this value after several attempts in this cadaveric study, although further scientific study is warranted.

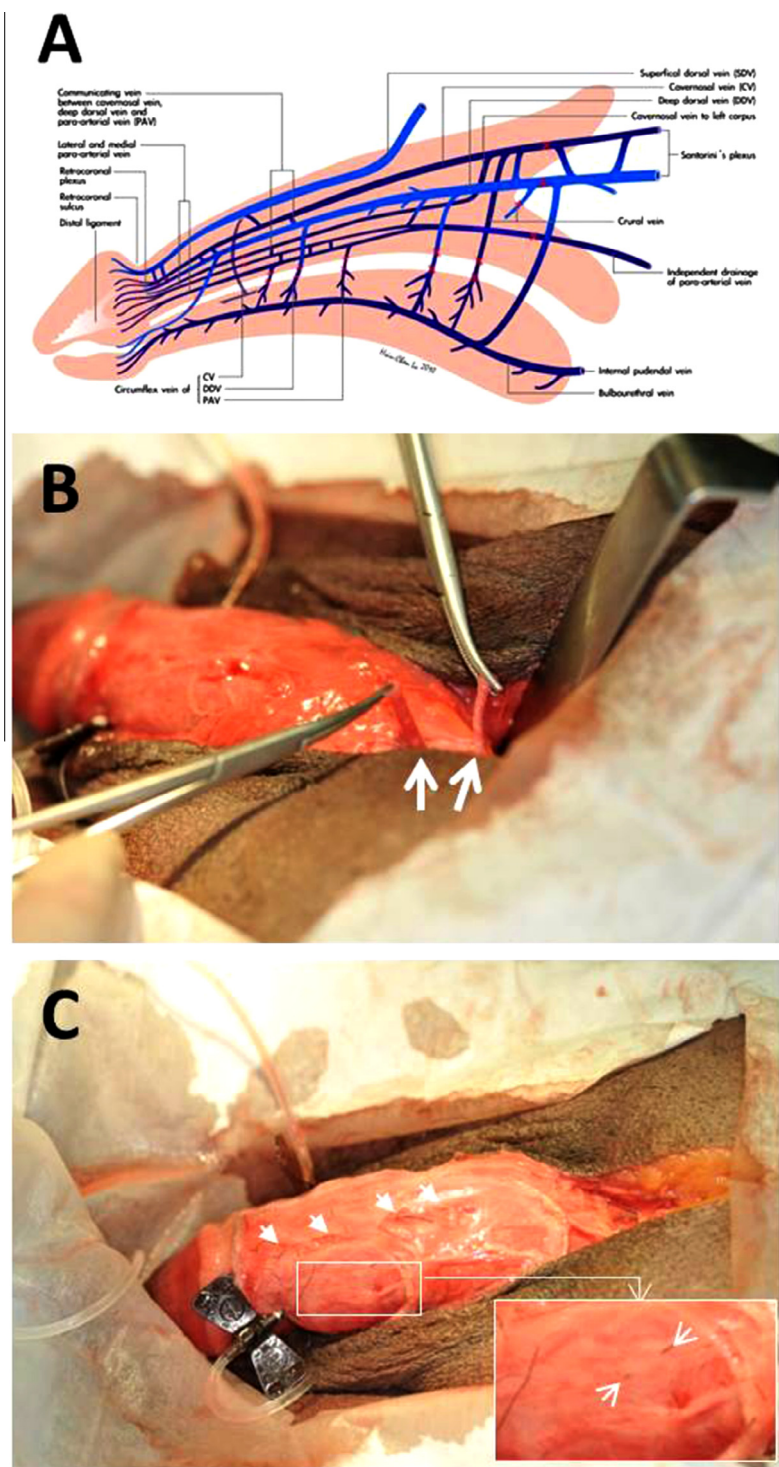
To accurately perform this type of study, the method for needle puncture and fixation is crucial. Therefore, a scalp needle puncture is recommended as described, as self-sealing of the cadaveric tissue is impossible, and the subsequent loss of water-tightness of the corpus cavernosum cannot be avoided. We advise that it should not be freely moveable and instead be firmly fixed in place with silk sutures. In addition, the technique for arterial ligation is paramount. It is understandable that the penile arterial supply, both the dorsal and cavernous arteries, is a drainage route rather than a perfusion

feeder in cadavers, as there is no blood pressure in the arterial lumen. We ligated the penile artery as the final step of this haemodynamic study to reduce the chance of damaging the tunica albuginea. Such damage would ruin the watertight milieu of the corpora cavernosa necessary for applying Pascal's law, which states that pressure applied to any part of an enclosed fluid at rest is transmitted undiminished to every portion of the fluid and to the walls of the containing vessel [17].

If penile venous stripping surgery is to be used in a clinical setting, care should be taken to spare those tissues critical to postoperative function, such as the nervous tissue, the arterial vessels, and the lymphatic, fibrous and muscle tissues. However, this was not essential in this cadaveric study, and thus it was permissible to detach the collagen or muscle fibres adherent to the penile shaft all the way to the pubic rami, to reduce the operative time. However, during venous surgery the perfect sealing of the emissary stump is more challenging in cadavers. Leaking colloids are readily encountered if the watertight milieu of the corpora cavernosa venous system has not been perfectly preserved. In addition, those veins between the corpora cavernosa and the corpus spongiosum remained untouched in the present study. These facts might partly explain why a significantly higher percentage of residual drainage remained (mean 15.6%, range 14.1–18.1) after both arteries and veins were closed. Furthermore, concerning the bulbospongiosus, ischiocavernosus and perineal muscles [18], previous reports appear to be in general agreement that these muscles can assist in erection via the spongiosus compressing the erectile tissues of the spongiosal bulb [19] and the ischiocavernosus compressing the penile crura, in turn, retarding the return of blood through the veins and thus assisting in maintaining an erection. It appears that this notion should be true.

In the present study an ICP of 90 mmHg was readily achieved in the seven cadavers, and the conventional anatomical knowledge (i.e., the singular significance of a lone DDV distribution) was found to be deficient. We removed the DDV, CVs and PAVs in sequence, leaving the corpora cavernosa intact, to study its independent drainage, which corresponded with clinical imaging observations. This study might help in understanding why a recurrence of ED after venous surgery is by no means unavoidable, as long as the haemodynamic roles of both the CVs and PAVs in the human penis are properly accounted for. In other words, a thorough scrutiny of the penile vasculature shows a complexity that could plausibly account for why physicians overlook 'residual veins' when performing penile venous surgery, and in subsequently misinterpreting these veins as 'recurrent' in the event of a disappointing postoperative result [20].

In conclusion, this study shows the separately significant contributions of the DDV, CVs and PAVs in the



**Figure 4** An illustration and photographs of penile venous stripping surgery. (A) This illustration stresses the positions of the ligatures placed on the venous stumps to render a watertight milieu of the corpora cavernosa and thus enable the application of Pascal's law. The DDV system was first removed, followed by the CV system, and the PAVs which were ligated only, in sequence. The sites of these ligatures should be as close to the tunica albuginea as possible. Finally, the penile artery was ligated at the branching point of the dorsal and cavernous artery proximally. Care should be taken, as a rupture of the tunica albuginea would ruin the watertight milieu necessary to apply Pascal's law. (B) Ongoing penile venous surgery; the DDV (left arrow) was first stripped and ligated closest to the tunica albuginea with 5-0 Nylon sutures, then the CV (right arrow) was similarly treated after cavernosometry. It was continued as proximal as possible. (C) The PAVs were segmentally ligated while the medial and lateral ones (inserted arrows) were meticulously treated after removing of the DDA and CV, which left a dorsal groove (arrows).



**Table 1** Summary data of the perfusion rate for an ICP of 90 mmHg in seven defrosted cadavers.

No. (age, years)	Cause of death	TOD (h)	Overall haemodynamics (PR, CPR,%) <sup>a</sup>	DDV removal (PR, CPR,%) <sup>b</sup>	CVs removal (PR, CPR,%) <sup>c</sup>	PAVs ligation (PR, CPR,%) <sup>d</sup>	After arterial ligation (PR, CPRAC) <sup>e</sup>	Remaining percentage
1 (40)	Homicide	9.5	29.0, 26.2, 100	15.6, 12.8, 51.1	9.6, 6.8, 22.9	6.5, 3.7, 11.8	3.7, 2.8	14.1
2 (47)	Colon cancer	8.8	32.7, 30.2, 100	12.8, 10.3, 65.9	9.7, 7.2, 10.3	7.0, 4.5, 8.9	4.5, 2.5	14.9
3 (58)	Suicide	10.0	45.5, 42.1, 100	20.3, 16.9, 59.9	15.3, 11.9, 11.9	10.5, 7.1, 11.4	7.1, 3.4	16.9
4 (59)	Lung cancer	9.0	24.6, 23.3, 100	10.5, 9.2, 60.5	5.7, 4.4, 20.6	4.5, 3.2, 5.2	3.2, 1.3	13.7
5 (70)	Renal cancer	9.0	15.8, 15.5, 100	5.0, 4.7, 69.7	4.1, 3.8, 5.8	3.1, 2.8, 6.5	2.8, 0.3	18.1
6 (87)	Liver cancer	7.0	94.0, 90.8, 100	36.5, 33.3, 63.3	30.1, 26.9, 7.0	16.5, 13.3, 15.0	13.3, 3.2	14.6
7 (67)	AMI	6.0	39.3, 35.4, 100	21.5, 17.6, 50.3	14.7, 10.8, 19.2	9.8, 5.9, 13.8	5.9, 3.9	16.7
Mean (60)	NA	9.0	30.2	60.5	11.9	11.4	2.8	11.6
(range)			(15.5–90.8)	(50.3–69.7)	(5.8–22.9)	(5.2–15.0)	(0.3–3.9)	(14.1–18.1)

PR, perfusion rate; CPR, corrected perfusion rate, mL/min for maintaining an ICP of 90 mmHg; %, drainage percentage of each corresponding component. AMI, acute myocardial infarction; NA, not applicable; TOD, interval after death before being refrigerated; CPRAC, calculated perfusion rate of the arterial contribution (mL/min) as it is assumed that the penile artery is a drainage source in cadavers. This was done after penile arterial ligation. Data derived.

<sup>a</sup> Before venous removal.

<sup>b</sup> After removal of the DDV.

<sup>c</sup> After removal of the CVs.

<sup>d</sup> After ligation of the PAVs.

drainage of the corpora cavernosa in the human penis. While the DDV does indeed have a predominant role in venous drainage, it is not, as the medical literature depicts, the lone conduit; as our study reveals, the reality of the venous system is much more complex than originally realised. Using this challenging model, we can calculate the probable drainage proportion of individual venous systems.

#### Conflict of interest

None.

#### Source of funding

None.

#### Acknowledgements

This study was inspired by the Microsurgery Potency Reconstruction Group, among whom extensive debate has taken place. We wish to thank Ms Hsiu-Chen Lu for her illustrations, Mrs Yi-Ting Wang, Luan-Hua Ho and Yu-Jen Serena Lin for their preparation of photographs for this manuscript.

#### Appendix A. Supplementary data

Supplementary data associated with this article can be found, in the online version, at <http://dx.doi.org/10.1016/j.aju.2013.04.002>.

#### References

- [1] Fitzpatrick T. The corpus cavernosum intercommunicating venous drainage system. *J Urol* 1975;**113**:494–6.
- [2] Moscovici J, Galinier P, Hammoudi S, Lefebvre D, Juricic M, Vaysse P. Contribution to the study of the venous vasculature of the penis. *Surg Radiol Anat* 1999;**21**:193–9.
- [3] Hsu GL, Hsieh CH, Wen HS, Chen YC, Chen SC, Mok MS. Penile venous anatomy. An additional description and its clinical implication. *J Androl* 2003;**24**:921–7.
- [4] Parona F. Imperfect penile erection due to varicosity of the dorsal vein: observation. (In Italian). *Giornale Italiano Delle Malattie Veneree E Della Pelle* 1873;**14**:71–6.
- [5] Wooten JS. Ligation of the dorsal vein of the penis as a cure for atonic impotence. *Tex Med J* 1902;**18**:325–8.
- [6] Lowsley OS, Rudea EA. Further experience of an operation for the cure of certain type of impotence. *J Int Coll Surg* 1953;**19**:69–77.
- [7] Wespes E, Schulman CC. Venous leakage. Surgical treatment of a curable cause of impotence. *J Urol* 1985;**133**:796–8.
- [8] Montague DK, Barada JH, Belker AM, Levine LA, Nadig PW, Roehrborn CG, et al. Clinical guidelines panel on erectile dysfunction: summary report on the treatment of organic erectile dysfunction. *J Urol* 1996;**156**:2007–11.
- [9] Chen SC, Hsieh CH, Hsu GL, Wang CJ, Wen HS, Ling PY, et al. The progression of the penile vein: could it be recurrent? *J Androl* 2005;**26**:53–60.
- [10] Wen HS, Hsieh CH, Hsu GL, Kao YC, Ling PY, Huang HM, et al. The synergism of penile venous surgery and oral sildenafil in treating patients with erectile dysfunction. *Int J Androl* 2005;**28**:297–303.
- [11] Hsu GL, Chen HS, Hsieh CH, Lee WY, Chen KL, Chang CH. Salvaging penile venous stripping surgery. *J Androl* 2010;**31**:250–60.
- [12] Tsai VFS, Chang MD HC, Liu SP, Kuo YC, Chen JH, Jaw FS, et al. Determination of human penile electrical resistance and implication on safety for electrosurgery of penis. *J Sex Med* 2011;**12**:2891–8.



- [13] Hsu GL, Chen HS, Hsieh CH, Lee WY, Chen KL, Chang CH. Clinical experience of a refined penile venous surgery procedure for patients with erectile dysfunction: is it a viable option? *J Androl* 2010;**31**:271–80.
- [14] Hsu GL, Hung YP, Tsai MH, Hsieh CH, Chen HS, Molodysky E, et al. Penile veins are the principal component in erectile rigidity: a study of penile venous stripping on defrosted human cadavers. *J Androl* 2012;**33**:1176–85.
- [15] Perper JA. Time of death and changes after death – Part I. Anatomical considerations. In: Spitz WU, editor. *Spitz and Fisher's medicolegal investigation of death*. 4th ed. Springfield: IL. Charles C Thomas; 2006. p. 87–127.
- [16] Hsu GL, Brock G, von Heyden B, Nunes L, Lue TF, Tanagho EA. The distribution of elastic fibrous elements within the human penis. *Br J Urol* 1994;**73**:566–71.
- [17] Halliday D. Pascal's principle, fluids. In: Halliday D, Resnick R, Walker J, editors. *Fundamentals of physics*. New York: John Wiley & Sons; 1997. p. 355–6.
- [18] Putz R, Pabsteds R. Pelvic diaphragm [floor]. Male and female external genitalia. In: Putz R, Pabsteds R, editors. *Sobotta atlas of human anatomy*. Philadelphia: Lippincott. Williams & Wilkins; 2001. p. 222–39.
- [19] Shafik A. Response of the urethral and intracorporeal pressures to cavernosus muscle stimulation: role of the muscles in erection and ejaculation. *Urology* 1995;**46**:85–8.
- [20] Cakan M, Yalcinkaya F, Demirel F, Ozgunay T, Altug U. Is dorsale penile vein ligation (DPVL) still a treatment option in veno-occlusive dysfunction? *Int Urol Nephrol* 2004;**36**:381–7.