

Neurological Complications after Deceased Donor Liver Transplant: A Case Series from a Public Sector Hospital

KANIMOZHI RATHINASAMY¹, SATISH LOGIDASAN², KARTHIK ARUN PRAKASAM³, SR KARTHIK⁴, GOWRI SHANKAR ANJENEYAN⁵



ABSTRACT

This is a case series of neurological complications which occurred after Deceased Donor Liver Transplant (DDLT) in a public sector hospital. The clinical presentations were bizarre. This is because patients with End Stage Liver Disease (ESLD) commonly have hepatic encephalopathy and postoperatively can present with similar clinical picture, like tremors and altered mentation. The first patient in the series presented with tremors due to Calcineurin Inhibitor (CNI) toxicity, second had Posterior Reversible Encephalopathy Syndrome (PRES), third with Osmotic Demyelination Syndrome (ODS) with coma and fourth with Extrapryamidal Syndrome (EPS). Patients 1 and 4 had involuntary movements and other clinical manifestations which interfered with recuperation in the postoperative period. So, the dosages of the immunosuppressants were adjusted and serum tacrolimus assay were serially monitored on alternate days. Case 3 developed PRES due to hypertension, as a result of high serum tacrolimus levels. The patient presented with headache and seizures, which if uncontrolled would have been lethal. In Case 4 clinical features and management of a patient who suffered prolonged coma due to ODS for about three months has been discussed. Also, the same patient had a cerebral infarct due to embolic phenomenon inspite of thromboprophylaxis. From this case series, it needs to be emphasised that postoperative occurrence of neurological complications are likely. So careful selection of the recipients, steady titration of immunosuppressants and watchful monitoring of the neurological signs are essential to improve the outcome of the transplant. Imaging of the brain, preferably Magnetic Resonance Imaging (MRI) should not be delayed to rule out other differential diagnosis.

Keywords: Alcoholism, Headache, Immunosuppression, Tremors

INTRODUCTION

This is a case series of neurological complications which occurred in four DDLT recipients, who presented in the institute between March 2017 and June 2019. The incidence of neurologic complications is around 15-30% in liver transplantation [1,2]. Clinical presentations of CNI toxicity, ODS, cerebrovascular accidents, cerebral opportunistic infections can occur [2]. Eventually leading to increased morbidity and mortality of the recipient. The mortality related to neurological complications is around 10.98% [2,3].

CASE SERIES

Case 1

This is a case of a liver transplant recipient who presented with coarse tremors due CNI toxicity in the immediate postoperative period. He was a 24-year-old ESLD patient that occurred secondary to hepatitis B virus, for whom DDLT was performed. He was started on Tacrolimus at 1 mg BD dosage on the first Postoperative Day (POD) and the daily dosage was escalated to 3 mg BD by the first week. Serum tacrolimus assay of 8 to 10 ng/mL was targeted, since this was considered an optimal level of immunosuppression to avoid acute cellular rejection and related complications in our institute. From the 12th day the patient gradually developed coarse tremors of hand which present both at rest and while doing physical activities. The tremors restricted his daily activities, ambulation, drug compliance which are essential for the graft survival. The corresponding serum tacrolimus assay was 14 ng/dL. Other causes for tremors were ruled out, except tacrolimus, which is known to cause the clinical presentation. Tablet Mycophenolate Mofetil (MMF) 500 mg BD was added and tacrolimus dose was reduced to 2 mg BD. In spite of reducing the dose, the patient did not show any symptomatic improvement. So, it was decided to discontinue tacrolimus and cyclosporine 500mg BD was added. The tremors resolved in three

days after stopping tacrolimus. His level of immunosuppression was stabilised and was discharged in the next week.

Case 2

A 42-year-old male patient with ESLD, due alcoholic cirrhosis, developed PRES after DDLT. The patient was epileptic and taking levetiracetam for the past 10 years. Serum tacrolimus assay was maintained around 8-10ng/L postoperatively. He had an acute cellular rejection with deranged liver enzymes, during the 8th postoperative day. So steroid pulse therapy using intravenous methylprednisolone 1 gm was administered. The patient was optimised and discharged on the 3rd week. On the 45th day, inspite of high serum tacrolimus, he had mild acute cellular rejection, and showed raised Liver Function Tests (LFT) and his blood pressures were high [Table/Fig-1]. The patient was admitted and amlodipine was started. Three days after admission, he had throbbing headache with hypertension. Within a few minutes he developed generalised tonic clonic seizure which was managed by intravenous lorazepam 5 mg. MRI brain showed hyperintense lesion in territories of posterior cerebral artery with subacute haemorrhage of size 31×15×21 mm in right posterior parietal cortex with surrounding vasogenic oedema, suggestive of PRES Blood pressures was optimised. Tacrolimus assays were planned to be kept in a lower range between 5 to 7 ng/mL. Hence, MMF 500 mg twice daily was added and tacrolimus dose was reduced. Based on the LFT, MMF dose was increased to 1 gm BD

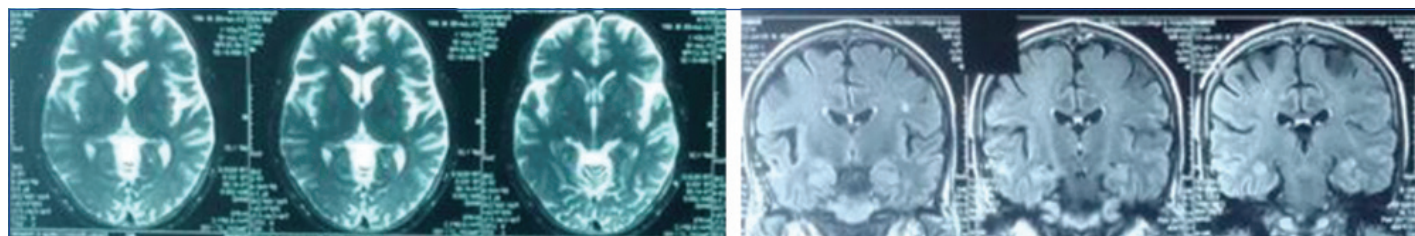
Day	Tacrolimus assay (ng/mL)	AST/ALT	BP mmHg
30 th	11.4	40/164	140/90
36 th	9.7	117/130	154/84
42 nd	9.0	111/118	170/90
45 th	8.4	167/171	184/100

[Table/Fig-1]: Postoperative tacrolimus levels, LFT and blood pressure.

and levetiracetam 500 mg was continued. His LFT got normalised. MRI taken one week later revealed a decrease in vasogenic oedema. The patient was asymptomatic, had no further headache or seizures and was discharged.

Case 3

This was a case of alcoholic ESLD patient, who suffered coma due to ODS and also had cerebral embolic infarct in the postoperative period. Preoperative blood biochemistry were within normal limits, Echo showed normal left ventricular systolic function, mild tricuspid regurgitation, MRI showed, T1 hyperintensity in the bilateral basal ganglia, suggestive of ESLD [Table/Fig-2].



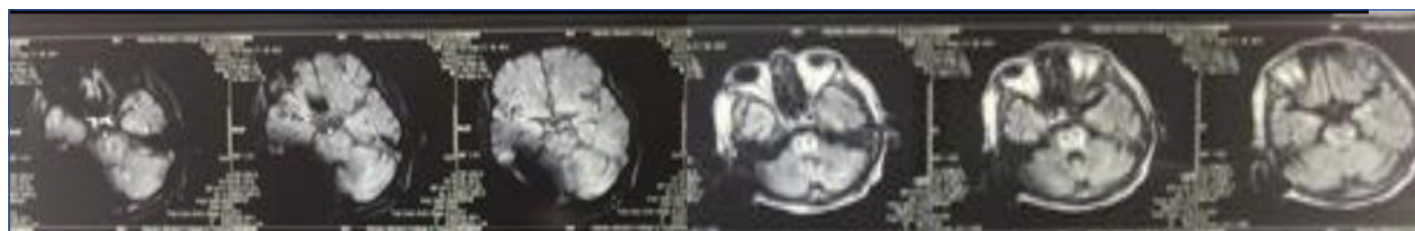[Table/Fig-2]: Preoperative MRI brain showing T1 Hyperintensity in the bilateral basal ganglia.

Tacrolimus 0.5 mg BD was started in day 1, then dose was escalated to 1.5 mg BD [Table/Fig-3]. He was on Low Molecular Weight Heparin (LMWH) 40U OD for thromboprophylaxis. Patients muscle power was only 3/5, had tremors in the upper limb and dysarthria. Tacrolimus toxicity was suspected it was switched over to cyclosporine, but there was no clinical improvement.

Day 1	Day 2	Day 3
1.5 ng/mL	5 ng/mL	8 ng/mL

[Table/Fig-3]: Tacrolimus assay values.

On the 6th day, the patient developed sudden Supraventricular Ventricular Tachycardia (SVT) with a heart rate of 190/min BP-74/50 mmHg. Carotid massage was given. Inj. Amiodarone loading dose 300 mg was given. The arrhythmia reverted in three minutes. Since then, the patient was drowsy and became comatose by 8th day he was managed with mechanical ventilation. MRI brain, done on the 11th POD, showed features suggestive of acute embolic infarct involving left middle frontal gyrus, bilateral gyri, right frontal white matter (lacunar) and left precentral gyrus (lacunar), extrapontine myelinosis due to osmolyte imbalance, hyperintensity in transverse pontine fibres [Table/Fig-4].



[Table/Fig-4]: MRI brain 11th POD showing ODS, embolic infarct, hepatic encephalopathy.

The patient was started on citicholine 500 mg OD, atorvastatin 20 mgHS, capsule amantadine 100 mg OD, Tablet Clopidogrel 75 mg OD. Gradually the patient regained consciousness over the next two months. It took another 120 days to gain the motor power and his tracheostomy was decannulated by 150th day. The patient was discharged the next week.

Case 4

This was case of EPS in an 18-year-old female, which aggravated after liver transplant. DDLT was done for ESLD due to Wilson's disease. Preoperatively, she had history of EPS with Parkinson's features, for which she was taking Levodopa 250 mg and Trihexyphenidyl 2 mg, for two years. The patients preoperative MRI brain showed hyperintensity in the outer margin of putamen.

The dose of tacrolimus was adjusted and her tacrolimus assay was adequately built. Tacrolimus assay was 1.5, 5,7 ng/mL on day 1, 3, and 7, respectively. Levodopa and trihexyphenidyl were stopped in the postoperative period, in view of the drug interactions, which might compromise the immunosuppression. From the 5th POD, she had dystonic limb movements, staccato speech and behavioral changes. Tacrolimus toxicity was suspected and was switched over to cyclosporine. But no improvement of symptoms was present. MRI revealed no new findings. In view of clinical deterioration in behaviour and movement disorder, levodopa 125 mg and trihexyphenidyl 1 mg were restarted in half of the original doses. The Parkinson's symptoms resolved and the patient was

discharged. Thus, the patient's immunosuppression and movement disorder, both were balanced and managed.

DISCUSSION

The predisposing factors for neurological complications are immunosuppression, sepsis, multiple organ failure, hepatic dysfunction and alcoholism [1]. Among the 112 cases done in our low volume centre four patients had suffered the neurological complications.

In the 1st case report except for the tremors other manifestations of CNI toxicity like hyperglycaemia, hypertension was not seen. Tremors are more severe due to tacrolimus than cyclosporine as suggested by Erro R et al., [4]. The tremors subsided after switching over to cyclosporine. Thus, the tremors due to CNI must be treated for the optimal outcome of the liver transplantation.

In case 2 PRES typically presented with headache and seizure, similar to the study by Cruz RJ et al., on 1923 liver recipients [5]. In PRES the endothelial cell dysfunction of the brain barrier results in vasogenic oedema. PRES can present as intracranial haemorrhage in 5 to 15% of patients [5]. It has unique CT or MRI imaging appearance with an incidence of 0.49% [6]. The most

common triggering factor is sudden surge in blood pressures [7]. PRES occurs more in patients taking cyclosporine rather than tacrolimus. Though the patient 2 was not on cyclosporine, had hypertension which was one of the toxic effects of higher tacrolimus levels. The management was to eliminate the triggering factor, which in present case was hypertension. Hence tacrolimus dose was reduced and immunosuppression maintained by adding MMF and BP was controlled in a stringent manner. Any liver transplantation patient with a headache and accelerated hypertension, it is advisable to do MRI brain [8].

In case 3 ODS developed while there was normal serum sodium. The common perception is that ODS is a dreadful complication that occurs after aggressive therapy for hyponatremia. But ODS

can develop in patients with low, normal, or elevated plasma levels of sodium [9,10]. The inability of brain cells to respond to rapid changes in osmolality of the extracellular compartment of the brain, leads to ODS [11]. ODS, occurs especially in alcoholic malnourished patients [11]. Optimising nutritional status of the recipients preoperatively, avoiding perioperative changes in the electrolytes, minimising the duration of the surgery thereby the major fluid shifts are recommended to avoid osmotic stress to the brain [12]. Timely imaging, supportive measures were done for this case.

Case 3 had embolic infarct inspite of thromboprophylaxis with LMWH. The stasis associated with clot formation during the SVT could have been the source of emboli, in case 3. In a retrospective study on 461 patients, postoperative atrial fibrillation occurred in 47 patients a median of three days after transplantation with embolic episodes [13].

Case 4 suggests the intricacies of polypharmacy in liver transplant [14] and knowing the drug interactions. The clinicians must be able to titrate doses, if clinical scenario warrants. It is essential that titration of immunosuppressants must be done on individual basis with anticipation and close monitoring for neurological disorders.

CONCLUSION(S)

Neurological complications can complicate the liver transplant surgery. So high index of clinical suspicion is essential. The discussed case of tacrolimus induced tremors, PRES, ODS and EPS would have turned the liver transplant futile, endangering the patient's life. So, there is a need for delicate titration of the immunosuppressive agents based on individual response. MRI brain must not be delayed if clinical scenario warrants.

REFERENCES

- [1] Zivkovic SA. Neurologic complications after liver transplantation. World Journal of Hepatology. 2013;5(8):409-16.
- [2] Yi SH, Li H, Yang Y, Lu MQ, Cai CJ, Xu C, et al. Major neurological complications following liver transplantation and their management. Nan Fang Yi Ke Da Xue Xue Bao. 2007;27(9):1310-13. Chinese. PMID: 17884765.
- [3] Lewis MB, Howdle PD. Neurologic complications of liver transplantation in adults. Neurology. 2003;61(9):1174-78. Doi: 10.1212/01.wnl.0000089487.42870.c6. PMID: 14610116.
- [4] Erro R, Bacchin R, Magrinelli F, Tomei P, Geroin C, Squintani G, et al. Tremor induced by Calcineurin inhibitor immunosuppression: A single-centre observational study in kidney transplanted patients. J Neurol. 2018;265(7):1676-83. Doi: 10.1007/s00415-018-8904-x. Epub 2018 May 18. PMID: 29777361.
- [5] Cruz RJ Jr, DiMartini A, Akhavanheidari M, Iacovoni N, Boardman JF, Donaldson J, et al. Posterior reversible encephalopathy syndrome in liver transplant patients: clinical presentation, risk factors and initial management. Am J Transplant. 2012;12(8):2228-36. Doi: 10.1111/j.1600-6143.2012.04048.x. Epub 2012 Apr 11. PMID: 22494636.
- [6] Bartynski WS, Tan HP, Boardman JF, Shapiro R, Marsh JW. Posterior reversible encephalopathy syndrome after solid organ transplantation. AJNR Am J Neuroradiol. 2008;29(5):924-30. Doi: 10.3174/ajnr.A0960. Epub 2008 Feb 13. PMID: 18272559; PMCID: PMC8128592.
- [7] Hobson EV, Craven I, Blank SC. Posterior reversible encephalopathy syndrome: A truly treatable neurologic illness. Perit Dial Int. 2012;32(6):590-94. Doi: 10.3747/pdi.2012.00152. PMID: 23212858; PMCID: PMC3524908.
- [8] Lening C, Agopian VG, Busuttill RW, Liebeskind DS. Incidence, etiology, and outcomes of altered mental status in the perioperative setting of liver transplantation. Neurohospitalist. 2018;8(3):124-28. Doi: 10.1177/1941874417738689. Epub 2017 Nov 7. PMID: 29977442; PMCID: PMC6022898.
- [9] Zheng YJ, Liang TB, Shen Y, Wang WL, Ke QH. Possible causes of central pontine myelinolysis after liver transplantation. World J Gastroenterol. 2004;10(17):2540-43.
- [10] Huq S, Wong M, Chan H, Crimmins D. Osmotic demyelination syndromes: Central and extrapontine myelinolysis. J Clinical Neuroscience. 2007;14:684-88.
- [11] Gankam Kengne F, Nicaise C, Soupart A, Boom A, Schiettecatte J, Pochet R, et al. Astrocytes are an early target in osmotic demyelination syndrome. J Am Soc Nephrol. 2011;22:1834-45.
- [12] Crismale JF, Meliambro KA, DeMaria S Jr, Bronster DB, Florman S, Schiano TD. Prevention of the Osmotic Demyelination Syndrome After Liver Transplantation: A Multidisciplinary Perspective. Am J Transplant. 2017;17(10):2537-45. Doi:10.1111/ajt.14317.
- [13] Koshy AN, Enyati A, Weinberg L. Postoperative atrial fibrillation and long term stroke in patients undergoing liver transplantation. AHA Journals. 2021;52:111-20.
- [14] Ganesh S, Almazroo OA, Tevar A, Humar A, Venkataramanan R. Drug metabolism, drug interactions, and drug-induced liver injury in living donor liver transplant patients. Clin Liver Dis. 2017;21(1):181-96. Doi: 10.1016/j.cld.2016.08.011. PMID: 27842771.

PARTICULARS OF CONTRIBUTORS:

1. Senior Assistant Professor, Department of Anaesthesiology, Government Stanley Medical College, Chennai, Tamil Nadu, India.
2. Associate Professor, Department of Anaesthesiology, Government Vellore Medical College, Vellore, Tamil Nadu, India.
3. Senior Assistant Professor, Department of Anaesthesiology, Government Stanley Medical College, Chennai, Tamil Nadu, India.
4. Senior Assistant Professor, Department of Anaesthesiology, Government Stanley Medical College, Chennai, Tamil Nadu, India.
5. Senior Assistant Professor, Department of Anaesthesiology, Government Stanley Medical College, Chennai, Tamil Nadu, India.

NAME, ADDRESS, E-MAIL ID OF THE CORRESPONDING AUTHOR:

Dr. Satish Logidasan,
13 Raji Street, Manavala Nagar, Thiruvallur, Tamil Nadu, India.
E-mail: drsatishlogi@gmail.com

PLAGIARISM CHECKING METHODS: [Jain H et al.]

- Plagiarism X-checker: Nov 24, 2022
- Manual Googling: Dec 20, 2022
- iThenticate Software: Jan 21, 2023 (6%)

ETYMOLOGY: Author Origin

AUTHOR DECLARATION:

- Financial or Other Competing Interests: None
- Was informed consent obtained from the subjects involved in the study? Yes
- For any images presented appropriate consent has been obtained from the subjects. Yes

Date of Submission: **Nov 16, 2022**

Date of Peer Review: **Dec 31, 2022**

Date of Acceptance: **Jan 30, 2023**

Date of Publishing: **Apr 01, 2023**