

# Warfarin-Induced Limb Contusion and Haematoma

SOUMYA<sup>1</sup>, DNYANESH MORKAR<sup>2</sup>, ANUSHREE DESHPANDE<sup>3</sup>

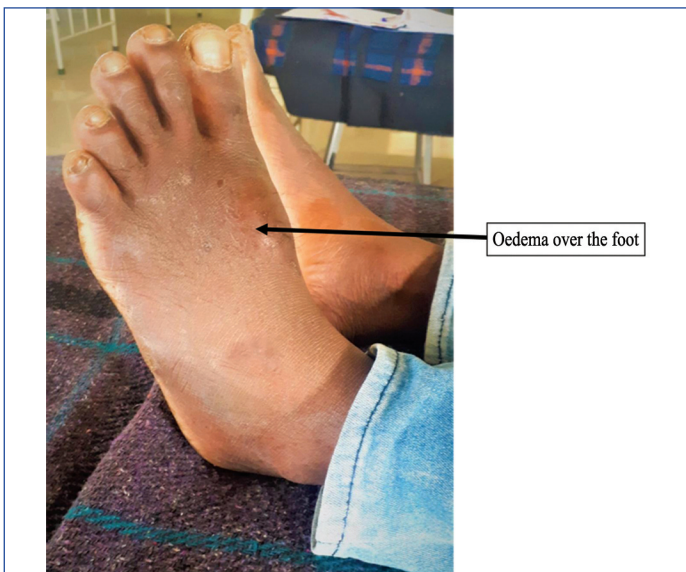
## ABSTRACT

Warfarin is a narrow therapeutic index drug with high potential to cause adverse effects. It is generally a preferred drug for the management of venous thrombosis. This case is an unusual presentation of left arm contusion and limb haematoma secondary to long-term warfarin use. A 32-year-old male patient was admitted with the complaints of left lower limb oedema and left upper arm oedema. He was on warfarin for dural sinus thrombosis for two years. The integrative analysis of patient clinical presentation, medication history, International Normalized Ratio (INR) level, Ultrasonography (USG) scan and Naranjo assessment showed the probable case of warfarin-induced left arm contusion and limb haematoma. The patient was successively managed with the administration of vitamin K, injection heparin, packed red blood cell and other supportive therapy after the withdrawal of the culprit drug. Thus, patients prescribed with warfarin should be looked at for this typical adverse event. Monitoring of anticoagulant therapy is vital for the positive clinical outcome and minimisation of adverse events. Clinical pharmacists have a key role to play in the patient safety and their inputs can fertilise the concept of pharmacist led anticoagulation clinic in India.

**Keywords:** Adverse drug reaction, Anticoagulant, Naranjo assessment

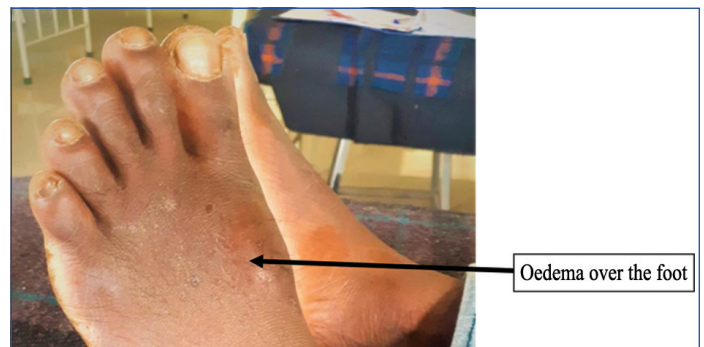
## CASE REPORT

A 32-year-old male patient was admitted with the complaints of left lower limb [Table/Fig-1] and left upper arm tenderness with pitting type oedema type oedema [Table/Fig-2] for 10 days. He had also experienced pain in right hypochondriac region from past seven days which was associated with generalised weakness and muscle cramps. The patient was chronic alcoholic (400 mL/week) over the past 10 years. Based on the Cut down, Annoyed, Guilty, and Eye-opener (CAGE) questionnaire, his drinking habit was categorised as 'hazardous'. He even regularly chewed tobacco. However, he had quit these habits two years back when he was diagnosed with dural sinus venous thrombosis and was treated with warfarin 5 mg OD and epoetin 100 mg OD.



**[Table/Fig-1]:** Hematoma over the left foot; tenderness and pitting oedema was present.

On physical examination, pallor and soft tenderness in right upper quadrant of the abdomen was observed. The laboratory test of the patient during the hospital stay is depicted in [Table/Fig-3]. USG scan was performed on left arm and left foot which revealed a diffused subcutaneous oedema involving deltoid muscle of the left



**[Table/Fig-2]:** Contusion of the left arm.

arm, whereas the left foot demonstrated well-defined hypoechoic area on dorsum in subcutaneous plane with no internal vascularity suggesting a haematoma. A USG abdomen scan concluded fatty liver. After correlating the present complaints, past medical history, laboratory investigation and USG scan reports the patient was diagnosed with left arm contusion and left foot haematoma secondary to warfarin therapy. Naranjo adverse drug reaction probability assessment scale was used to classify this Adverse Drug Reaction (ADR) as probable with a score of +6 [Table/Fig-4]. The primary treatment objectives were to reverse the warfarin overdose and resolve or evacuate haematoma. Following the diagnosis, his anticoagulation was reversed with vitamin K 10 mg OD, he was subsequently prescribed with injection pantoprazole 40 mg OD, injection ondansetron 4 mg OD as he complained of vomiting on the second day, injection iron sucrose 100 mg on day 1. On day 2 syrup lactulose 15 ml TID for prophylaxis of hepatic encephalopathy, tablet chymotrypsin BID for prophylaxis of i.v. cannula related swelling, injection tramadol SOS and on day 3, he was given injection amoxicillin and potassium clavulanate 625 mg BID, injection heparin 5000 units BID. He was administered with 5 units of packed red blood cells on day 2, day 4, day 6 and day 12. All these treatments continued and on the thirteenth day, INR levels and haemoglobin were found to be 1.3 and 9.1 mg/dl, respectively. The patient was advised for surgery to evacuate the haematoma but he declined due to financial constraints and took discharge against medical advice.

Parameters	Day1	Day 3	Day 5	Day 7	Day 13	Normal ranges
<b>Hematological test</b>						
Hemoglobin	6.5	5.9	7.8	-	9.1	12-16 mg/dL
Packed Cell Volume (PCV)	25.9	20.7	22.5	-	26.1	40-50%
Mean Corpuscular Volume (MCV)	83	-	-	-	-	60-95 fl
Mean Corpuscular Haemoglobin (MCH)	26.2	-	-	-	-	27-32 pg
Mean Corpuscular Haemoglobin Concentration (MCHC)	31.6	-	-	-	-	31-35 g/dL
Red Blood Cells (RBC)	2.89	2.52	2.81	-	3.17	4.5-5.5×10 <sup>6</sup> μ/l
Platelets	301	332	350	-	328	150-450×10 <sup>3</sup> μ/l
Differential count	7.9	6.13	5.52	-	9.54	4.0-10×10 μ/l
Neutrophils	77	70	75	-	75	40-75%
leukocytes	14	25	27	-	31	20-40%
Eosinophils	01	04	01	-	01	1-7%
Absolute Eosinophil Count (AEC)	150	-	-	-	-	30-350 cells/mL
<b>Coagulation test</b>						
Prothrombin Time (PT) (control)	11.2	13.5	13.4	13.4	13.4	9.5-12.5 seconds
(test)	27.2	29.5	23.2	21.4	17.4	
(ratio)	2.37	2.20	1.60	1.7	1.3	
International Normalised Ratio (INR)	2.39	2.38	1.67	1.70	1.33	<1.2
aPTT(control)	32.5	44.7	58.2	-	36.4	21-35 seconds
(test)	39.7	36.4	36.4		49.6	
(ratio)	1.22	1.23	2.08		1.36	
<b>Liver function test</b>						
Total bilirubin	0.6	-	-	1.5	-	0.3-1.3 mg/dL
Indirect bilirubin	0.3	-	-	0.4	-	0.2-0.8 mg/dL
SGOT	52	-	-	24	-	0-30 IU/L
SGPT	35	-	-	12	-	10-28 IU/L
Alkaline phosphatase	102	-	-	107	-	60-300 U/L
<b>Renal function tests</b>						
Uric acid	-	-	6.7	7.7	-	2.5-8.5 mg/dL
Urea	32	-	30	26	-	6-24 mg/dL
Serum creatinine	1.8	-	0.9	0.8	-	0.6-1.3 mg/dL
<b>Electrolytes</b>						
Sodium	136	-	135	143	-	135-148 mmol/L
Potassium	4.4	-	4.3	3.9	-	3.5-5.0 mmol/L
chlorides	95	-	102	104	-	95-105 mmol/L

[Table/Fig-3]: Laboratory test results.

aPTT: activated Partial Thromboplastin clotting Time; SGOT: Serum Glutamic-Oxaloacetic Transaminase; SGPT: Serum Glutamic Pyruvic Transaminase

S. No.	Questions	Yes	No	Don't know	Obtained score
1.	Are there previous conclusive reports on this reaction?	+1	0	0	0
2.	Did the adverse event appear after the suspected drug was administered?	+2	-1	0	+2
3.	Did the adverse event improve when the drug was discontinued or a specific antagonist was administered?	+1	0	0	+1
4.	Did the adverse event reappear when the drug was re-administered?	+2	-1	0	0
5.	Are there alternative causes that could solely have caused the reaction?	-1	+2	0	+2
6.	Did the reaction reappear when a placebo was given?	-1	+1	0	0
7.	Was the drug detected in blood or other fluids in concentrations known to be toxic?	+1	0	0	0
8.	Was the reaction more severe when the dose was increased or less severe when the dose was decreased?	+1	0	0	0

9.	Did the patient have a similar reaction to the same or similar drugs in any previous exposure?	+1	0	0	0
10.	Was the adverse event confirmed by any objective evidence?	+1	0	0	+1
<b>Total score</b>					<b>+6</b>

[Table/Fig-4]: Naranjo adverse drug reaction probability assessment scale.

On discharge, rivaroxaban 10 mg OD, chymotrypsin TID, amoxicillin plus potassium clavulanate 625 mg BID for five days were prescribed. The patient was educated about warfarin-related adverse reactions along with a yellow card. At the time of discharge, the INR level was stabilised to 1.3 and was advised to follow-up after one month.

## DISCUSSION

Cerebral dural sinus venous thrombosis is one of subtypes of venous thrombosis accounting for 30% of all strokes in India and primarily caused by the high levels of pro-coagulants, which may be associated with inherited thrombophilia. Presently available treatment options

include anti-thrombotic therapy with heparin and oral anticoagulants like warfarin [1]. Similarly, in this case, the patient was treated with warfarin 5 mg over a period of two years. It interferes with coagulation pathways by inhibiting Vitamin K Epoxide Reductase Complex 1 (VKORC 1) leading to decline in biosynthesis of vitamin K dependent pro-coagulants [2]. The pharmacodynamic response of warfarin is uncertain due to the influence of genetic polymorphism of VKORC1 and CYP2C9 which plays a key role in warfarin metabolism. In some individuals, coagulopathy develops rapidly due to previously existing factor VII deficiencies [3]. Warfarin-related adverse events such as bleeding are frequently reported by patients.

Moreover, any trauma can rupture the blood vessel, forming a contusion that appears like bruises and further when the same blood leaks into a tissue compartment it forms a haematoma [4]. Some of the rare haematomas are reported in locations like intraspinal, gastric intramural, retropharyngeal and iliopsoas region [5]. This case report focuses on limb haematoma, an unusual location for haematoma. Patients on long-term warfarin therapy require INR monitoring between 2 to 3, as slight change in diet, compliance to therapy, disease, age or a patient's response to drug might cause fluctuations in INR levels. However, haematomas are also reported between 2 to 3 therapeutic INR levels [6].

Similarly, in this patient the INR levels at the time of admission were 2.39. Drug induced haematoma are generally observed among the patients prescribed with anticoagulants (warfarin), antiplatelets (aspirin, dipyridamole, clopidogrel) [7]. Additionally, Aspirin and related phenolic drugs are also reported to cause life-threatening drug reactions called pemphigus [8]. There are no guidelines for diagnosis of warfarin associated adverse reaction, however this case was diagnosed based on clinical presentation, past medication history and USG scan which directly points towards haematoma secondary to warfarin therapy. The management strategies for warfarin related ADR requires attaining the INR levels below 2. This can be achieved by termination of warfarin therapy, administration of vitamin K, prothrombin complex concentrator and fresh frozen plasma in case of fatal bleeding [9]. A case series reported the dose of vitamin K can vary from 10 mg to 50 mg and maximum up to 110 mg [10]. Thus, treatment plan in this patient correlated with the standard treatment strategy. Patients are also transfused with fresh frozen plasma [11]. Alternatively, this patient was transfused with packed red cells to correct the haematological parameters.

The administration of warfarin therapy and achieving stable INR levels in Cerebral Venous Thrombosis (CVT) is a challenging task and sometimes leads to complications like haemorrhage and formation of haematoma. However, warfarin nomogram can aid in appropriately adjusting the dose based on target INR level the dose can range from 5 mg to 12.5 mg [12]. About 6.7% of total hospital admission is due to serious adverse drug reactions, further adding healthcare cost and financial burden on patients [13]. However, a multicentered study found that direct oral anticoagulants like rivaroxaban and dabigatran are safer and efficacious when compared to warfarin in the treatment of Cerebral Venous Thrombosis (CVT). Although, Direct Oral AntiCoagulants (DOACs) do not necessitate INR monitoring, they typically are more expensive than warfarin and lack information on

cost-effectiveness among CVT patients [14]. Therefore, by substituting brand drugs by generic medicine can minimise healthcare cost due to medication [15].

## CONCLUSION(S)

Haematoma in the limbs resulting from warfarin overdose is rare but a serious adverse reaction which can affect the patient's mobility. Thus, patients on warfarin should be properly monitored for this adverse effect. Clinical pharmacist could play a significant role in the detection of such rare events and suggest a better therapeutic approach which might give birth to the concept pharmacist led anticoagulation clinics where patient can be educated about the INR level, anticoagulants, its side effects, interactions and encourage consumer to self-report drug allergies.

## Acknowledgment

We would like to thank our Principal, KLE College of Pharmacy, Belagavi for encouragement and also thank Dr. Deepthi Avvaru for her constant support during this work.

## REFERENCES

- Anadure RK, Wilson V, Sahu S, Singhal A, Kota S. A study of clinical, radiological and etiological profile of cerebral venous sinus thrombosis at a tertiary care center. *Med J Armed Forces India*. 2018;74(4):326-32.
- Wu S, Chen X, Jin DY, Stafford DW, Pedersen LG, Tie JK. Warfarin and vitamin K epoxide reductase: a molecular accounting for observed inhibition. *Blood*. The Journal of the American Society of Hematology. 2018;132(6):647-57.
- Kaur N, Pandey A, Shafiq N, Gupta A, Das R, Singh H, et al. Genetic and nongenetic determinants of variable warfarin dose requirements: a report from North India. *Public Health Genomics*. 2022;25(1-2):52-60.
- Ozturk M, Ipekci A, Kiyak SK, Akdeniz YS, Aydin Y, Ikizceli I, et al. Bleeding complications in warfarin-treated patients admitted to the emergency department. *J Clin Med Res*. 2019;11(2):106.
- Yadav P, Yadav S, Pathak S. Warfarin: A double-edged sword. *Journal of Family Medicine and Primary Care*. 2019;8(9):3045.
- Shendre A, Parmar GM, Dillon C, Beasley TM, Limdi NA. Influence of age on warfarin dose, anticoagulation control, and risk of hemorrhage. *Pharmacotherapy: The Journal of Human Pharmacology and Drug Therapy*. 2018;38(6):588-96.
- Ulubay M. Spontaneous retroperitoneal hematoma associated with combined warfarin and ticlopidine use. *Urology Case Reports*. 2019;22:34. Doi: 10.1016/j.eurc.2018.09.004.
- Kumar Chaudhary R, Bhandari R, Doshi B, Karoli SS, Spoorthi Marrapalli S, Ganachari MS. Gefitinib induced Pemphigus Vulgaris with PRIDE complex. *J Oncol Pharm Pract*. 2022;28(6):1465-73.
- Yee J, Kaide CG. Emergency reversal of anticoagulation. *West J Emerg Med*. 2019;20(5):770.
- Levine M, Pizon AF, Padilla-Jones A, Ruha AM. Warfarin overdose: a 25-year experience. *J Med Toxicol*. 2014;10(2):156-64.
- Frontera JA, Gordon E, Zach V, Jovine M, Uchino K, Hussain MS, et al. Reversal of coagulopathy using prothrombin complex concentrates is associated with improved outcome compared to fresh frozen plasma in warfarin-associated intracranial hemorrhage. *Neurocritical Care*. 2014;21(3):397-406.
- Arif KM, Rahman MA. A review of warfarin dosing and monitoring. *Faridpur Medical College Journal*. 2018;13(1):40-43.
- Formica D, Sultana J, Cutroneo PM, Lucchesi S, Angelica R, Crisafulli S, et al. The economic burden of preventable adverse drug reactions: A systematic review of observational studies. *Expert Opinion on Drug Safety*. 2018;17(7):681-95.
- Yaghi S, Shu L, Bakradze E, Salehi Omran S, Giles JA, Amar JY, et al. Direct oral anticoagulants versus warfarin in the treatment of cerebral venous thrombosis (ACTION-CVT): A multicenter international study. *Stroke*. 2022;29(2):728-38.
- Chaudhary RK, Philip MJ, Santhosh A, Karoli SS, Bhandari R, Ganachari MS. Health economics and effectiveness analysis of generic anti-diabetic medication from jan aushadhi: An ambispective study in community pharmacy. *Diabetes Metab Syndr*. 2021;15(6):102303.

### PARTICULARS OF CONTRIBUTORS:

- Pharm-D, Department of Pharmacy Practice, KLE College of Pharmacy, KAHER, Belagavi, Karnataka, India.
- Consultant Physician, Department of General Medicine, KLES Prabhakar Kore Hospital and Medical Research Centre, Belagavi, Karnataka, India.
- Assistant Professor, Department of Pharmacy Practice, KLE College of Pharmacy, KAHER, Belagavi, Karnataka, India.

### NAME, ADDRESS, E-MAIL ID OF THE CORRESPONDING AUTHOR:

Anushree Deshpande,  
Assistant Professor, Department of Pharmacy Practice,  
KLE College of Pharmacy, KAHER, Belagavi, Karnataka, India.  
E-mail: anushreedeshpande@klepharm.edu

### AUTHOR DECLARATION:

- Financial or Other Competing Interests: None
- Was informed consent obtained from the subjects involved in the study? Yes
- For any images presented appropriate consent has been obtained from the subjects. Yes

### PLAGIARISM CHECKING METHODS: [Jain H et al.]

- Plagiarism X-checker: Sep 26, 2022
- Manual Googling: Dec 02, 2022
- iThenticate Software: Dec 29, 2022 (2%)

### ETYMOLOGY: Author Origin

Date of Submission: Sep 24, 2022

Date of Peer Review: Nov 15, 2022

Date of Acceptance: Jan 10, 2023

Date of Publishing: Apr 01, 2023