



# **A Case Report on Dental Management of a Child with Attention Deficit Hyperactivity Disorder**

**Khan Shumayla<sup>a++\*</sup>, Goswami Mousumi<sup>a#</sup>,  
Saxena Aditya<sup>a†</sup> and Shivangani<sup>a++</sup>**

<sup>a</sup> *Department of Paediatric and Preventive Dentistry, I.T.S Dental College, Hospital & Research Centre, Greater Noida, Uttar Pradesh, India.*

## **Authors' contributions**

*This work was carried out in collaboration among all authors. All authors read and approved the final manuscript.*

## **Article Information**

### **Open Peer Review History:**

This journal follows the Advanced Open Peer Review policy. Identity of the Reviewers, Editor(s) and additional Reviewers, peer review comments, different versions of the manuscript, comments of the editors, etc are available here: <https://www.sdiarticle5.com/review-history/102197>

**Case Report**

**Received: 17/04/2023**

**Accepted: 21/06/2023**

**Published: 27/06/2023**

## **ABSTRACT**

One of the most prevalent neurobehavioral disorder among children in school-age population is attention-deficit hyperactivity disorder. Children with ADHD have severe levels of hyperactivity, impulsivity, and inattentiveness. These symptoms have a negative impact on social and emotional growth as well as academic achievements. Antidepressants and stimulant medications are typically used to treat it. To get the most cooperation from patients who have ADHD, dentists treating them must be familiar with the symptoms of the condition and its accompanying characteristics. The medications used to treat the disorder must also be known to them because many of these medications have negative effects on the orofacial and systemic physiology and may interact with oral therapeutic agents. This case study aims to report a case of a 10-year-old girl with ADHD and to confer dental management approaches for all of the significant oral health problems that these children may have.

<sup>++</sup> *Post Graduate Student;*

<sup>#</sup> *Professor and Head;*

<sup>†</sup> *Professor;*

<sup>\*</sup>*Corresponding author: Email: khanshumayla1@gmail.com;*

**Keywords:** Attention-deficit hyperactivity disorder; behaviour management; dental management.

## 1. INTRODUCTION

In accordance with the Diagnostic and Statistical Manual of Mental Disorders, Fifth Edition (DSM-VTM), ADHD is characterised as a persistent pattern of inattention and/or hyperactivity-impulsivity that hinders with performance or development. And it has indications that are present in multiple circumstances (such as at the house, school, or place of employment; among peers or family members; in other activities) and also has a negative impact on social, educational, or academic performance before the age of 12 and for at least six months, a number of symptoms must be present, together with behaviour that is below the child's level of development [1,2].

Impulsiveness, hyperactivity, and inattention are the three prominent manifestations of ADHD. These symptoms hinders the patient's in performing basic oral hygiene measures which makes them more prone to dental caries and they are additionally at a higher risk of enduring traumatic dental injuries. Developmental language issues, anxiety, oppositional-defiant behaviours, problems with fine motor skills and coordination, and particular learning challenges are some of the potential underlying medical conditions of ADHD.

The purpose of this case report is to describe the non-pharmacological behaviour management techniques that can be used in child with ADHD and it also sheds insights on how early diagnosis and effective preventive dental treatment can contribute in averting more major dental problems.

## 2. CASE REPORT

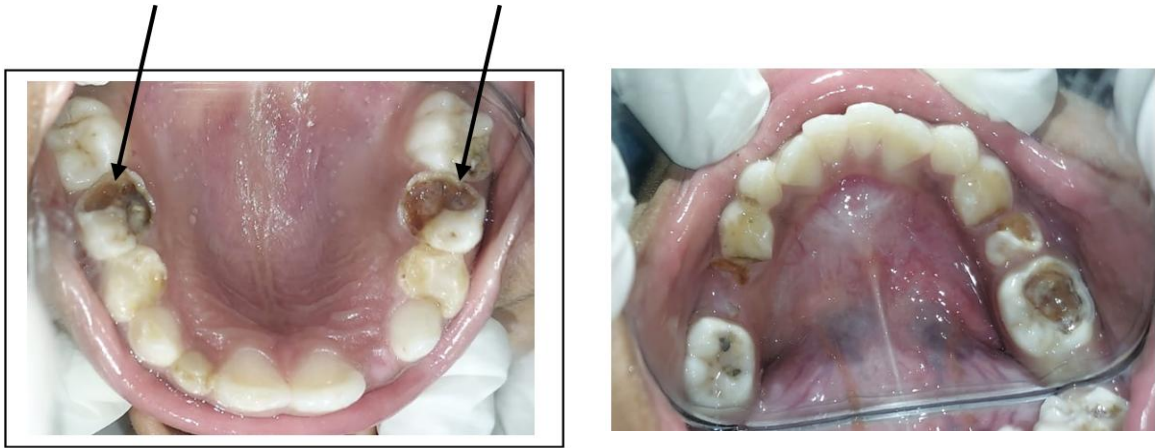
A 10 years old female patient who was diagnosed with ADHD reported to the department of paediatric and preventive dentistry at ITS dental college, Greater Noida with the chief complaint of pain in the lower left back teeth region since 4-5 days. This was patient's first dental visit and there was no contributory family history, pre-natal and post-natal history reported.

The patient's mother reported that the diagnosis of ADHD was done 2 years back and since then

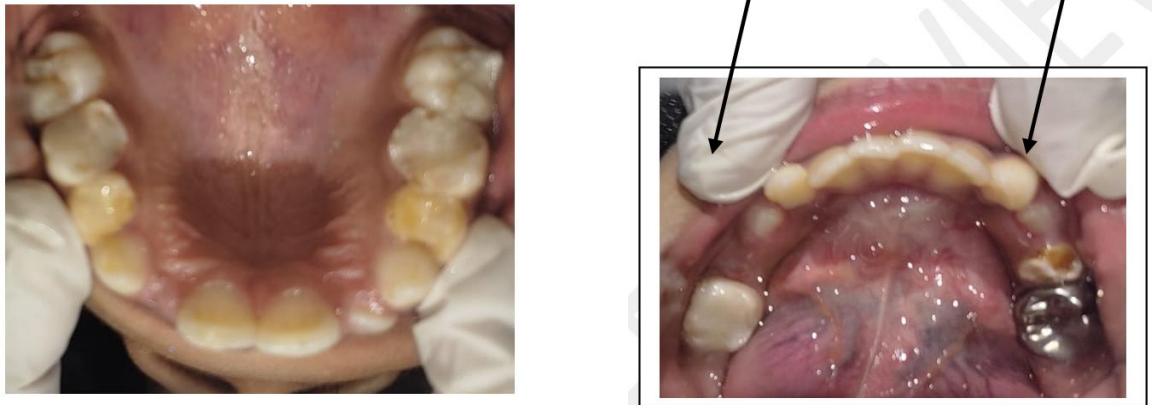the child was under medication (Methylphenidate (Ritalin LA)). Patient's mother also reported that the patient has a habit of pencil biting. The Intraoral examination revealed no relevant soft tissue finding but there was deep dental caries in relation to 36 which was tender on percussion, Dental caries was also seen in 55, 65, 26, 46, and 75; root stump with respect to 85 was present, Grade II mobility was seen in 52, 74, 75 and also mild stains and calculus were present (Fig. 1). Intraoral periapical radiographs were recommended and upon a thorough clinical and radiographic evaluation, the tooth number 36 (Fig. 3). was diagnosed with chronic irreversible pulpitis, Grade II mobile 52, 74, 75, Dental caries in 55, 65, 26, 46, 74 and Chronic generalized marginal gingivitis. Hence a comprehensive treatment plan was designed suitable to the child's condition.

The first visit included a complete oral examination as well as a comprehensive medical and dental history were recorded. According to the Frankel behaviour rating scale, the patient exhibited a positive behaviour so an emergency access opening was done in 36 as the child was in pain.

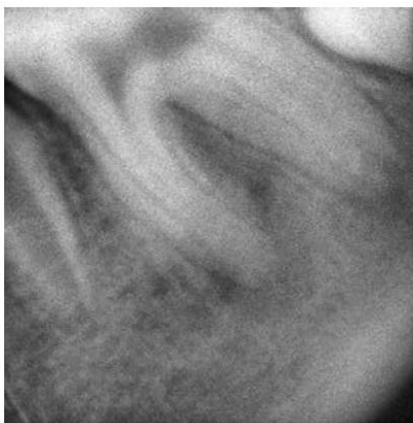
In the subsequent appointments behaviour management techniques such as tell-show-do and audio visual aids were used while oral prophylaxis was carried out which was followed by restorations of 55, 65, 26, 46, and 75. In the following visits endodontic treatment with respect to 36 was completed and a Stainless steel crown was placed (Figs. 2, 4). The child was mostly cooperative but sometimes became exceedingly agitated and showed signs of irritability and even became little uncooperative towards treatment in case of long appointments. To counter these behaviours morning appointments were scheduled an hour after the patient had her medication also suitable Non-Pharmacological behaviour management techniques like positive reinforcement was used in the form of compliments and reasonable rewards were given to appreciate good behaviour, and if appointments lasted longer than expected then frequent breaks/time-outs were given which helped us carry out her treatment effectively.



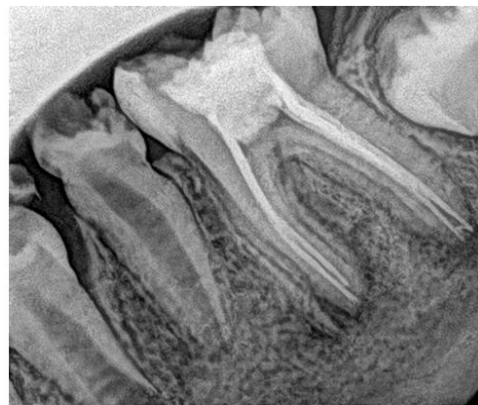
**Fig. 1. Pre-operative Intraoral photographs showing dental caries wrt 55, 65, 26, 36, 46, and 75**



**Fig. 2. Post-operative Intraoral photographs showing restorations in 55, 65, 26, 46 and Stainless steel crown wrt 36**



**Fig. 3. Pre-operative Intraoral periapical radiograph of 36**



**Fig. 4. Post-operative Intraoral periapical radiograph of 36**

### 3. DISCUSSION

For a Pedodontic team, treating an ADHD patient can be quite challenging. Nevertheless, they can be successfully treated provided their treatment needs and level of cooperation are carefully assessed. The oral health problems that are typically documented in the literature were all present in this child. (3) Dental treatment for children who display behavioural problems may entail the use of sedation or general anaesthesia. Yet, due to her age and willingness to cooperate, we were able to successfully treat her without the aid of any pharmacological means. The failure to take the prescribed medication was only seldom linked to instances of uncooperativeness. Therefore, it is crucial to check that the patient has taken the medication before beginning of the dental treatment [3]. She was at a significant risk for developing caries as a result of a combination of xerostomia caused by side effect of the drug Methylphenidate and also her inability to practise proper oral hygiene. ADHD is believed to affect between 3% and 5% of school-aged children, with boys outnumbering girls by a factor of three. Attention deficit hyperactivity disorder is five times more common in males than in girls, according to Polanczyk et al's systematic review, which estimates the prevalence at 5.3% worldwide [4]. The majority of young children (60%) display signs of both lack of attention and hyperactivity-impulsivity. However, lack of attention is prevalent in around 25% of individuals with ADHD, and it is frequently associated by slower intellectual processing and response times [5]. The majority of symptoms in the remaining 15% of individuals pertain to hyperactivity and impulsivity, which are occasionally (often in middle or high school) accompanied by alcohol and drug misuse [5]. Although the majority of theories centre on aberrant brain activity that is hereditary in nature, the precise cause of ADHD is still unknown. However investigations have demonstrated that it may be a complex neurological illness brought on by the combination of risk factors from the environment, including genetic, biological, psychological, and environmental factors [6,7].

Children with ADHD are five times more likely to have family members who also have the disease. High rates of drinking disorder, aggressive personalities, psychological disorders, and anxiety disorders are found in fathers of children with ADHD, and it is likely that they also had ADHD, ODD (Oppositional Defiant Disorder), or CD (Conduct disorder) as a child which indicates

a genetic connection [7,8]. Most children with the condition exhibit decreased total cerebral volumes and significant decreases in both grey and white matter in the frontal lobes, as determined by various anatomic brain imaging studies which points to disorder's vast scope of aetiologies [8]. Three kinds of ADHD exist, according to the DSM-IV i.e.; combined, inattentive, and predominantly hyperactive/impulsive. Patients with the mixed subtype, which is the most common, have symptoms that are consistent with both inattention and hyperactivity/impulsivity as was the case in our patient. Children who have the mixed subtype but are too young to show signs of inattention are typically described as having the mostly hyperactive/impulsive subtype. Inattentive (restrictive), the fourth subtype was added by DSM-V, occurs when the inattentive criterion is met but no more than two hyperactive/impulsive symptoms have been present for six months [1,9].

### 4. CLINICAL FEATURES

Inattention, hyperactivity, and impulsivity, which are hallmarks of ADHD, typically start to show up in elementary school. Nonetheless, the diagnosis of ADHD occurs before the age of 4 in 50% of cases, which has also led to the belief that it is a developmental condition. It is the most prevalent cognitive disorder among school-aged children and, in about 30% of instances, it lasts throughout adolescence and adulthood. Developmental issues such as Academic/educational challenges (dyslexia and/or language disorders), anxiety, oppositional-defiant behaviours, problems with fine motor skills as well as coordination, are some of the potential comorbidities of this disorder. Additionally, these children also struggle to retain shorter instructions and suffer from deficiencies in short-term auditory memory [6,10,11].

### 5. DENTAL REPERCUSSIONS OF ADHD

The children in this group are more likely to have dental caries because they fail to brush their teeth adequately and have poor oral hygiene habits, they also have a higher chance of developing molar-incisor hypoplasia, and suffer trauma. Based on information from the 1997 Health Survey of England, it was concluded that hyperactive children were twice as likely to sustain a facial or dental injury as the control group. This can be related to their involvement in

violence as a result of conduct disorder especially during adolescent period. These children tend to have poor salivary flow as well as elevated plaque indices. They also frequently display behaviours like nail-biting and bruxism, and experience abuse from peers [5,12,13,14].

## 6. DENTAL MANAGEMENT APPROACHES

Behaviour modification, Educational (counselling of both parents and child); Pharmacological management and necessary changes to lifestyle are some of the methods to manage these cases [3,15,16,17,18].

Planning oral care for paediatric patients with ADHD includes:

1. Plaque control by integrating correct brushing technique, using mouthwash and interdental aids like dental floss or interdental brushes.
2. Use of topical fluorides for effective prevention of caries.
3. Pit and fissure sealants can be employed as a preventive strategy in newly erupted teeth.
4. Diet modification such as reduction in consumption of refined carbohydrates and sugary food.
5. Routine dental check-up for early detection of dental caries.
6. Behaviour modification techniques such as TSD, positive reinforcement.
7. Behaviour management through pharmacological means such as nitrous oxide sedation can be employed.
8. Parental counselling and education.

## 7. CONCLUSION

Any ambient stimuli have the potential to both positively and negatively impact people with ADHD hence dentists can face an additional difficulty when treating children with ADHD. Pedodontists in particular should have the necessary knowledge to be in the forefront of making accurate diagnosis and needs to be aware of the modifications that must be made to achieve optimal oral health because of behavioural concerns, medications, and high risk for oral diseases in these patients. Caries preventive strategies and regular follow up are recommended for maintaining oral health in ADHD patients.

## ETHICAL APPROVAL

As per international standard or university standard written ethical approval has been collected and preserved by the author(s).

## CONSENT

As per international standard or university standard, Parental written consent has been collected and preserved by the author(s).

## COMPETING INTERESTS

Authors have declared that no competing interests exist.

## REFERENCES

1. The Diagnostic and Statistical Manual of Mental Disorders— 5th edition (DSM-5™)—See more at: <http://www.adhdinstitute.com/assessment-diagnosis/diagnosis/dsm-5tm/#sthash.EOi3Fvor.dpuf>  
Available: <https://www.psychiatry.org/psychiatrists/practice/dsm>
2. Rader R, McCauley L, Callen EC. Current strategies in the diagnosis and treatment of childhood attention-deficit/ hyperactivity disorder. *Am Fam Physician*. 2009Apr 15;79(8):657-665  
Available: <https://www.aafp.org/pubs/afp/issues/2009/0415/p657.html>
3. Sinha S, Praveen P, Rani SP, Anantharaj A. Pedodontic considerations in a child with attention deficit hyperactivity disorder: Literature review and a case report. *International Journal of Clinical Pediatric Dentistry*. 2018May;11(3):254.  
Available: <https://doi.org/10.5005/jp-journals-10005-1522>
4. Hidas A, Noy AF, Birman N, Shapira J, Matot I, Steinberg D, Moskovitz M. Oral health status, salivary flow rate and salivary quality in children, adolescents and young adults with ADHD. *Archives of oral biology*. 2011Oct 1;56(10):1137-41.  
Available: <https://doi.org/10.1016/j.archoralbio.2011.03.018>
5. Polanczyk G, de Lima MS, Horta BL, Biederman J, Rohde LA. The worldwide prevalence of ADHD: A systematic review and metaregression analysis. *Am J Psychiatry* 2007Jun;164(6):942-948.  
Available: <https://doi.org/10.1176/ajp.2007.164.6.942>

6. Efron D, Kilpatrick NM. Attention deficit hyperactivity disorder: a review and guide for dental professionals. *J Disability Oral Health*. 2002;3(1):7-12. Available:[https://www.stephenhancocks.com/download.php?op=view\\_article&article\\_id=52](https://www.stephenhancocks.com/download.php?op=view_article&article_id=52)
7. Friedlander AH. Attention-deficit hyperactivity disorder: setting the record straight. *Spec Care Dentist*. 2004 SepOct;24(5):249. Available:<https://doi.org/10.1111/j.1754-4505.2004.tb01700.x>
8. Friedlander AH, Yagiela JA, Paterno VI, Mahler ME. The pathophysiology, medical management, and dental implications of children and young adults having attention-deficit hyperactivity disorder. *Journal of the California Dental Association*. 2003Sep 1;31(9):669-78. Available:<https://pubmed.ncbi.nlm.nih.gov/14560871/>
9. Frances A, Pincus HA, Widiger TA, Davis WW, First MB. DSM-IV: work in progress. *The American Journal of Psychiatry*. 1990 Nov 1;147(11):1439-48. Available:<https://doi.org/10.1176/ajp.147.11.1439>
10. Soma Y, Nakamura K, Oyama M, Tsuchiya Y, Yamamoto M. Prevalence of attention-deficit/hyperactivity disorder (ADHD) symptoms in preschool children: Discrepancy between parent and teacher evaluations. *Environ Health Prev Med*. 2009;14(2):150-154. Available:<https://doi.org/10.1007%2Fs12199-008-0075-4>
11. Felicetti DM, Julliard K. Behaviors of children with and without attention deficit hyperactivity disorder during a dental recall visit. *ASDC J Dent Child*. 2000Jul-Aug;67(4):246-249,231. Available:<https://pubmed.ncbi.nlm.nih.gov/10997239/>
12. Broadbent JM, Ayers KM, Thomson WM. Is attention-deficit hyperactivity disorder a risk factor for dental caries? A casecontrol study. *Caries Res*. 2004Jan-Feb;38(1):29-33. Available:<https://doi.org/10.1159/000073917>
13. Chau YC, Peng SM, McGrath CP, Yiu CK. Oral health of children with attention deficit hyperactivity disorder: systematic review and meta-analysis. *Journal of Attention Disorders*. 2020May;24(7):947-62. Available:<https://doi.org/10.1177/1087054717743331>
14. Kilbride K, Kelly E, FitzGerald K. ADHD and oral health. *Journal of the Irish Dental Association*. 2022 Dec 1. Available:<https://doi.org/10.58541/001c.71291>
15. Gudadhe K, Lamba G, Nagpal D, Chaudhari P. Diagnosis and management of attention-deficit hyperactivity disorder patient in dental operatory. *International Journal of Medical and Dental Case Reports*. 2019;6(1):1-4. Available:<http://dx.doi.org/10.15713/ins.ijm dcr.117>
16. Paszynska E, Krahel A, Pawinska M, Dmitrzak-Węglarz M, Perczak A, Słopeń A, Gawriolek M. Management for Caries Prevention in ADHD Children. *International Journal of Environmental Research and Public Health*. 2022Jun17;19(12):7455. Available:<https://doi.org/10.3390%2Fijerph19127455>
17. TA AS, Ummer M, Alowairdhi AA, Alsubait AK, Aljuhani SM, Alzahrani AA, Alqahtani AA. Management of Attention-Deficit Hyperactivity Disorder Children for Dental Procedures. *Cureus*. 2023Apr1;15(4). Available:<https://doi.org/10.7759/cureus.36989>
18. Drumond VZ, Souza GL, Pereira MJ, Mesquita RA, Amin M, Abreu LG. Dental caries in children with attention deficit/hyperactivity disorder: a meta-analysis. *Caries Research*. 2022 Mar 22;56(1):3-14. Available:<https://doi.org/10.1159/000521142>

© 2023 Shumayla et al.; This is an Open Access article distributed under the terms of the Creative Commons Attribution License (<http://creativecommons.org/licenses/by/4.0>), which permits unrestricted use, distribution, and reproduction in any medium, provided the original work is properly cited.

*Peer-review history:*

The peer review history for this paper can be accessed here:  
<https://www.sdiarticle5.com/review-history/102197>